

# Low-frequency ultrasound debridement (Sonoca-185) in acute wound management: A case study

Shannon MK, Williams A & Bloomer M

## Abstract

There are numerous evidence-based wound debridement techniques that promote wound healing. However, some of these techniques may cause discomfort and pain for the patient and can be costly for the health care provider. A new, non-invasive wound debridement technique known as low-frequency ultrasonic debridement (LFUD) has been used for the removal of unhealthy tissue and bacterial load in wound management in the clinical setting. This paper reports the use of LFUD by a skin integrity clinical nurse consultant (CNC) as an adjuvant wound debridement and healing technique in a patient with a parastomal abscess. LFUD was found to benefit this patient in terms of expedited wound healing and increased comfort, enabling the patient to have a successful skin graft that led to complete wound closure and discharge from hospital in a timely manner.

*Keywords: debridement, wound bed preparation, antibacterial, wound healing, ultrasound, nurse-led intervention.*

## What is already known

Successful wound healing requires wound bed preparations and promotion of granulation and healing. Numerous techniques exist that aim to facilitate wound healing, with advantages and disadvantages for the patient and clinician already known.

## What this paper adds

LFUD is a new technique available to skin integrity clinicians that results in efficient wound bed preparation, promotes healing by stimulating the inflammatory process and healing cascade, whilst also having an antimicrobial effect. This treatment offers an alternative to surgical/sharp debridement and an adjunct to wound care and management and potentially results in reduced length of stay and increased patient comfort.

## Introduction

Wound bed preparation is vital for wound healing. Studies have shown that wound healing is improved with correct wound bed preparation, which includes appropriate debridement, infection control and moisture management<sup>1-4</sup>. There are numerous debridement techniques available to remove devitalised, infected and/or necrotic tissue from the wound bed to promote wound healing. These include conservative and sharp wound debridement, autolytic, enzymatic, mechanical, chemical, biological or parasitic debridement and, more recently, low-frequency ultrasound debridement (LFUD). In the case study reported in this paper, LFUD technique was used to prepare the wound bed and aid in wound closure for a patient with a parastomal abscess. This new wound management initiative was a two-year project that commenced in October 2010 and was funded by the Department of Health, Victoria, Australia, in collaboration between the skin integrity and podiatry services in a metropolitan public hospital in Victoria.

## Literature review

Research on conservative and sharp wound debridement, which involves the use of scalpel, scissors, or laser to cut

### Meagan K Shannon\*

MN, DipMngmnt, DipCritCare, RN  
Skin Integrity Clinical Nurse Consultant  
Peninsula Health, VIC, Australia  
Tel +61 3 9788 1471  
Email mshannon@phcn.vic.gov.au

### Allison Williams

RN, PhD  
Associate Professor, School of Nursing and  
Midwifery, Faculty of Medicine, Nursing and  
Health Sciences, Monash University  
VIC, Australia

### Melissa Bloomer

MN(Hons), MNP, MPET, GCDE, GCPET,  
Crit Care Cert, BN, RN, FACN  
School of Nursing and Midwifery, Faculty of  
Medicine, Nursing and Health Sciences, Monash  
University, VIC, Australia

\*Corresponding author

away dead tissue, has shown that all have advantages and disadvantages<sup>2,5</sup>. Sharp debridement is performed in an aseptic environment and is considered fast-acting and selective as it creates a blood-rich, clean wound surface in which granulating tissue can form<sup>6-8</sup>. However, as opposed to conservative debridement, it can be painful for the patient and costly, especially if an operating room is required<sup>5</sup>.

Autolytic debridement is achieved by using the body's own enzymes via wound products such as transparent films, hydrogels and hydrocolloids that rehydrate and liquefy necrotic tissue, and is usually painless<sup>5</sup>. Research has shown that this method is effective for wound healing by removing black, necrotic tissue and slough, but is considered a slow process<sup>5-9</sup>, thus increasing the risk of infection<sup>5</sup>. Enzymatic debridement utilises plant enzymes and ureas to rapidly digest necrotic tissue proteins. However, the need for a medical prescription and secondary dressings make this an expensive option and the treatment may produce inflammation and/or discomfort for the patient<sup>6</sup>. Mechanical debridement of necrotic tissue, which includes hydrotherapy, allows a dressing to proceed from moist to wet and then is manually removed to debride necrotic tissue<sup>7</sup>. As this technique is non-selective, it may traumatise healthy or granulating healing tissue which may cause maceration or infection, and while it is relatively cheap, it can be time-consuming and painful<sup>5-8</sup>.

Chemical debridement is a technique that utilises bacteriocidal and bacteriostatic agents which can be cytotoxic to healthy granulation tissue and may be rendered inactive in a wound that contains blood or pus<sup>5-7</sup>. Studies have demonstrated that this method remains controversial as benefits need to be closely observed against any disadvantageous effects on wound healing<sup>9,10</sup>. Biological or parasitic debridement usually consists of sterile maggot larvae (*Lucilia sericata*) being introduced into a wound to secrete proteinase enzymes that help degrade necrotic tissue, digest bacteria and stimulate formation of granulation tissue<sup>5</sup>. While it is relatively cheap and fast, it can be painful and unpleasant, and is contraindicated in patients with life-threatening, deep-tracking wounds and bleeding abnormalities<sup>5,6,7,10,11</sup>. Other wound management therapies, such as negative pressure wound therapy (NPWT), can complement acute and chronic wound healing, with research supporting its effectiveness<sup>12</sup>. This therapy was used in conjunction with LFUD in this case study.




Figure 1. LFUD Sonoca-185.

LFUD (Figure 1) is a relatively new technique used for wound debridement and to improve wound healing by perpetuating the wound healing cascade. LFUD was introduced to alleviate the pressure on operating rooms, decrease patient length of stay, enable debridement for patients who are unable to tolerate an anaesthetic, and facilitate follow-up and ongoing care in the community by a multidisciplinary team<sup>13,14</sup>. This technique removes unhealthy tissue, decreases bacterial load or bioburden, and is considered non-invasive because it uses ultrasound waves (frequencies >20,000 cycles per second) in much the same way as dentists remove plaque<sup>15</sup>. It has been reported that LFUD has numerous advantages, which include excellent wound bed preparation with antibacterial capabilities, minimal blood loss, improved patient safety and comfort, and cost savings due to decreased use of antibiotics, prevention of amputation and improved wound outcomes, particularly for patients who do not respond to standard wound care<sup>13-19</sup>. Compared to traditional conservative wound treatment, LFUD can expedite healing by removing impediments to healing whilst preserving a healthy, granulating wound bed that helps support successful skin closure via other surgical means such as skin grafting<sup>20</sup>.

LFUD technology has been used outside Australia for many years. Currently, there is no Australian published data on the use of LFUD<sup>13,14</sup>. International research has shown that most LFUD studies<sup>16-19</sup> have included either patients with chronic leg or diabetic foot ulcers except one study<sup>15</sup> that included patients with four large, non-healing surgical wounds which were debrided in preparation for skin closure via skin grafting. This study reported 107 LFUD treatments (range 6–15) on 17 patients over eight months. The outcome was that 53% of patient wounds had complete healing, 35% had at least a 50% reduction in wound size, and 12% experienced a 20–30% reduction in wound size. After commencing LFUD treatments, no patients required antibiotic treatment.

The choice of wound debridement technique is dependent on the patient, availability of resources, the skill or qualification of the clinician, and cost. Each individual patient requires a considered assessment prior to the use of any debridement technique to ensure best practice for best patient outcomes.

## LFUD procedure

The LFUD consists of a generator and a sonotrode hand piece (Figure 2) attached to tubing connected to a sterile 500-millilitre bag of normal saline. A foot pedal connected to the generator is used to disperse the ultrasound to the sonotrode head. Debridement is achieved via normal saline being streamed through the tubing to the sonotrode head with high-frequency ultrasound waves<sup>17</sup> to create cavitation or oscillating micro-gas bubbles of the saline<sup>18</sup>. The streaming, steady mechanical forces applied to all exposed surfaces disturbs the wound tissue where unhealthy tissue is washed or suctioned away and healthy tissue is stretched and 'tipped' into an inflammatory process or healing cascade, ultimately



Figure 2. Sonotrobes.

debriding and healing at the same time<sup>13,18</sup>. Amplitude or speed of the ultrasound waves can be adjusted on the generator according to the patient's tolerance, debridement and/or antibacterial needs<sup>13,17</sup>.

The period of debridement is calculated by the surface area of the wound divided by three, giving a minimum treatment time for antibacterial effect<sup>13</sup>. The clinician may choose to continue treatment over the estimated time to remove all visible unhealthy tissue depending on the patient's tolerance. It is typical to initially treat the wound with a topical anaesthetic, such as Emla cream, to reduce sensitivity and improve patient tolerance. For example, neuropathic wounds may require no anaesthetic agents.

### Considerations when using LFUD

There are three different styles of sonotrope heads (Figure 3) which can be used to debride the wound: hoof, double ball and spatula. The hoof creates a shower head spray, the spatula creates a one-directional spray and the double ball creates a circular, multidirectional spray<sup>14</sup>. The clinician makes the decision on which type of head to use based on the type of wound. For example, a cavity wound requires multidirectional spray; therefore the double ball would be preferred. An undulated flat surfaced wound would require a shower spray; therefore the hoof may be used. The spatula head is useful for large, flat-surfaced wounds.

Infection control principles and personal protection measures are observed at all times when utilising the LFUD technique. Due to the potential spray associated with the LFUD technique, a one-metre clearance zone is maintained, shield mask and gown are highly recommended and appropriate wipe down of the clearance zone using recommended infection control wipes or detergents to prevent cross-infection is essential<sup>14</sup>.

### The case study

The patient is a 66-year-old, married female living at home with her husband. She has a history of Crohn's disease, with a bowel resection in 1997 and colostomy formation in 2003, chronic obstructive pulmonary disease, cholecystectomy, anaemia, asthma and gastro-oesophageal reflux disease. In 2008 she underwent a parastomal hernia repair with mesh,

and a total hip replacement in July 2010, complicated by infection and requiring inpatient rehabilitation for almost two months. Whilst an inpatient at rehabilitation recovering from the hip surgery, she developed abdominal pain, nausea, vomiting and fever with an increased white cell count and pus in the colostomy site requiring readmission to the acute hospital.

Investigation revealed a fistula into the abdominal wall had developed with infection around the stoma site. A laparotomy was performed and the parastomal abscess was drained. Four days later, the abdominal mesh inserted during a previous hernia repair was removed and the stoma was re-sited.

On admission, her blood chemistry was within normal limits except an elevated white cell count and neutrophils. Her haemoglobin was slightly below accepted levels at 10.1 g/dL with total protein and calcium also below the recommended levels. The patient was considered to be within the healthy weight range for her age as assessed by a dietitian. Wound swabs showed small gram-positive and negative bacilli with a lot of degenerative cell debris. The patient's medication regimen post-laparotomy is detailed in Table 1.

Negative pressure wound therapy (NPWT) was applied at all times in between LFUD debridement treatments at 80 mm/Hg using sterile gauze as the medium of choice and changed twice weekly. The NPWT aided exudate management, increased the vascular supply and assisted with development of granulation tissue on the wound bed.

### Rationale for LFUD

Surgical debridement was the first choice for this patient prior to the use of LFUD due to the complexity of the patient's wound. NPWT had been used on the wound for less than four weeks and discussions were held with the covering general surgical team in regards to goals and outcomes for this patient. A skin integrity clinical nurse consultant (CNC) referral was made four weeks after the laparotomy and revision of stoma (Figure 4). This referral was made to expedite timely debridement for this patient as there were concerns over multiple and subsequent anaesthetics and

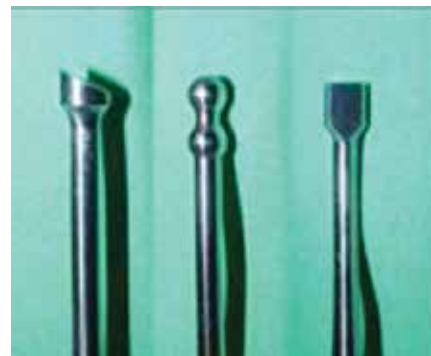

Figure 3. Sonotrope heads – hoof, ball and spatula.

Table 1. The case study patient's medication regimen.

Medication	Dose	Route	Frequency
Ceftriaxone	1 gm	IV	Daily
Metronidazole	500 mg	IV	Three times per day
Prednisolone	15 mg	Orally	Mane
Aspirin	100 mg	Orally	Mane
Enoxaparin sodium	20 mg	Subcutaneous	Daily
Furosemide	40 mg	Orally or IV	Mane
Humira	40 mg	Subcutaneous	Fortnightly
Oxycodone IR	5–10 mg	Orally	PRN four hourly
Oxycontin SR	5 mg	Orally	Twice per day
Ondansetron	4–8 mg	Orally or IV	Three times per day
Maxalon	10 mg	Orally or IV	Four times per day

delays in operating room bookings necessary for sharp wound debridement. The skin integrity CNC was given responsibility to care for this patient's wound in consultation with the general surgical team.

Following patient consent, the initial LFUD treatment was of 48 minutes in duration due to the size of the wound and the amount of devitalised tissue. The hoof sonotrode head was chosen for the directional spray. As the pain experienced by the patient was minimal, the amplitude was set to a maximum effect of 100% for debridement with the normal saline flow (lavage) set at 20%. The patient was given oral opiate pain relief of Oxycodone 5 mg. Concurrent suction was used to control any saline splash and general infection control principles were adhered to. Undermining of the bridge tissue was noted between the old stoma site and laparotomy site. Improvement was seen in the abdominal swelling (Figure 5), periwound (surrounding skin) and overall skin integrity

from first sighting, which was four weeks post-admission date. NPWT was used to continue to support granulation and management of exudate post-LFUD treatment.

The second treatment of LFUD was of 47 minutes' duration using the hoof and double ball sonotrode head with concurrent suction. The hoof was used on the flat surfaces of the wound and the double ball head was used in the cavity and sinus areas that were exposed upon treatment. 'Bridge' tissue was necrotic and required extensive debridement. LFUD revealed a large proximal right sinus of 8 centimetres (cm). There was noted undermining of the right side of the wound by 2.5 cm (very close to the stoma) and a proximal undermining flap of 4 cm (Figure 6). For this treatment, the amplitude was decreased to 80% and the saline flow was increased to 40% due to the patient experiencing 7/10 pain in the sinus and cavity areas.

## Jackson-Pratt® Hemaduct® Drains

Jackson-Pratt®, the leading name in wound drainage products, introduces Hemaduct® wound drains, the next generation in design and performance.

The Jackson-Pratt® brand Hemaduct® wound drain is uniquely designed with a system of multiple channels and lumens that are interconnected through a series of internal portals.

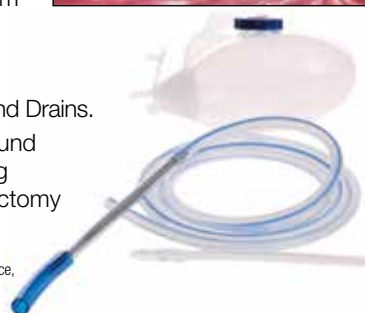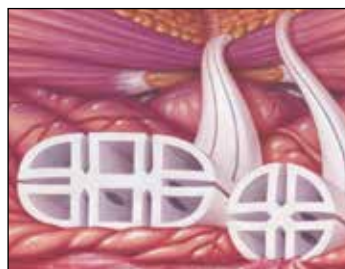The revolutionary design of the Hemaduct® wound drain ensures drain patency and uninterrupted drainage of fluid from the patient's wound.

## NEW Medline Wound Drains

Medline is proud to introduce the new range of Medline Wound Drains.

Medline manufactures and supplies a full line of closed wound drainage products for various surgical procedures including orthopaedic, plastics, general surgery, neurological, mastectomy and breast augmentation.

©2012 Medline Industries, Inc. Medline is a registered trademark of Medline Industries, Inc. One Medline Place, Mundelein, IL 60060. Hemaduct and Jackson-Pratt are registered trademarks of Cardinal Health, Inc. and distributed by Medline.



**Medline has a comprehensive range of silicone wound drains for the Australian and New Zealand Market.**



For further information, please contact  
**1800-MEDLINE**



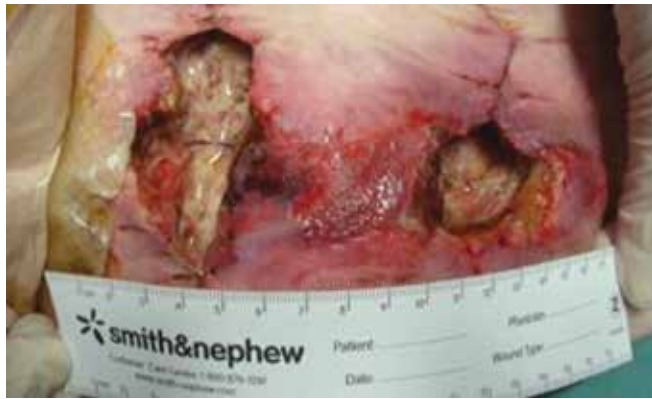

Figure 4. First view of wound post-laparotomy and revision of stoma.

The third treatment of LFUD was of 35 minutes' duration. The right proximal wound depth decreased by 3 cm to measure 5 cm in depth, the right side of wound of 2.5 cm depth was resolved (very close to the stoma) and the proximal flap remained 4 cm deep (Figure 7). The hoof sonotrode head was used for the flat surfaces of the wound and the double ball sonotrode head was used for the undermining cavity and sinus areas. Amplitude was adjusted to 100% with flow adjusted to 40% according to the patient's tolerance and suction was simultaneously applied. The double ball revealed a 4 cm left distal tunnel. This section of wound treatment was limited due to the patient's severe pain.

The final LFUD treatment was of 25 minutes' duration using the hoof sonotrode head with amplitude of 80% and a flow of 25% that had been adjusted to the patient's pain tolerance. Due to the lower flow rate, shorter treatment time duration and smaller wound size, suction was not required (Figure 8).

## Outcomes

The patient's length of stay was 66 days with the four LFUD treatments occurring over a 10-day period. NPWT was continued for just under nine weeks. There was successful wound healing of over 60% within five days of commencing LFUD. Within another three days the wound size had decreased by almost another 50%. The patient returned to rehabilitation care and gained sufficient wound granulation

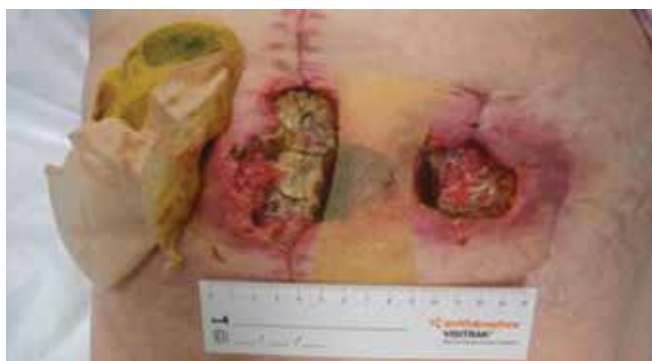

Figure 5. Post first LFUD treatment of 48 minutes' duration.

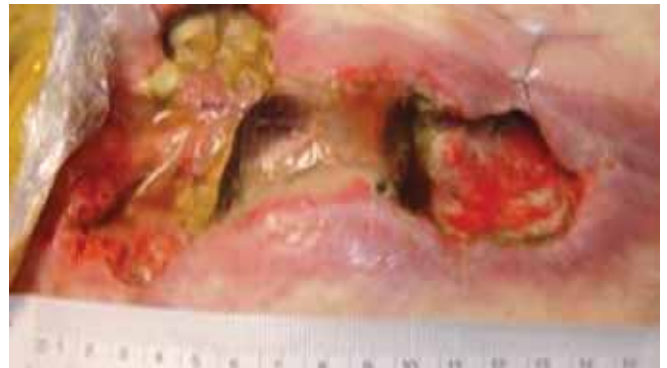

Figure 6. Post second LFUD treatment of 47 minutes' duration.

tissue with maintenance NPWT to have the wound surgically grafted 12 days after the final LFUD treatment. Recovery was uneventful post-skin graft and the patient was discharged home.

## Discussion

Whilst the LFUD technique was valuable for this patient's wound management, the time taken to use this technique by the skin integrity CNC must be acknowledged. We recommend a combination of LFUD and conservative sharps wound debridement to manage such a large wound based on our experience in this case study. The conservative sharps wound debridement would remove the bulk of the obvious unhealthy tissue and allow the LFUD to remove the last of the unhealthy tissue without damaging the wound bed whilst still having the benefits of an antimicrobial effect and instigation of the healing cascade. Despite this, LFUD proved to be an optimal technique for wound debridement and wound bed preparation in conjunction with NPWT for this patient as the outcome was complete wound closure with skin graft and discharge home.

## Conclusion

The use of LFUD as an adjunct in the healing or improving of chronic wounds was supported by this case study. The outcome for this patient with a parastomal abscess has been positive as complete wound closure was obtained. The LFUD achieved all the expected outcomes for this wound in that the

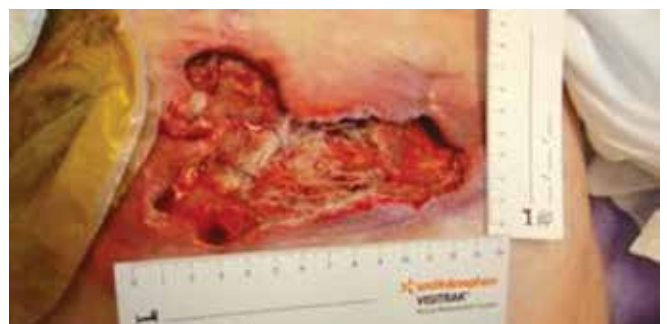

Figure 7. Post third LFUD treatment of 35 minutes' duration. Wound size decreased by over 60%.

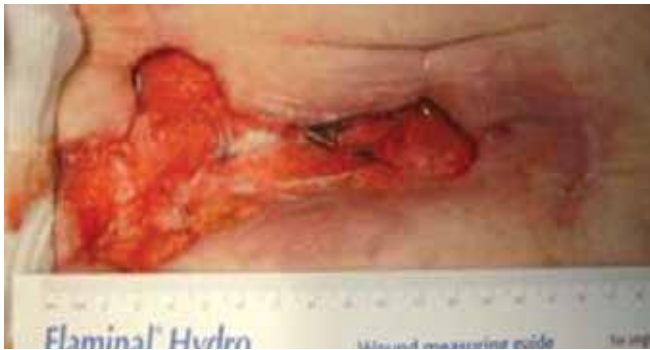

Figure 8. Post fourth LFUD treatment of 25 minutes' duration. Wound size decreased by almost another 50%.

wound bed preparation was acceptable for skin grafting by removing unhealthy tissue and bioburden, while controlling the patient's level of discomfort and pain. The patient required minimal medication including anaesthetic agents and analgesics, and no intra-hospital transfer was required with cost benefits for the treating hospital. In addition, treatment time leading to health benefits for the patient was reduced. Given the wound care for this patient was led by the skin integrity CNC and the ability to utilise the LFUD in the clinical setting, there was the capacity to maintain a degree of flexibility with treatment times, thus allowing for other patient care needs.

Whilst LFUD is identified as an excellent modality for wound debridement, the need to continue embracing other well-known debridement techniques has not been ignored. Instead, LFUD is now considered to be another arsenal for skin integrity services and can be used as an adjunct in the debridement and antibacterial management of wounds. Further research to support the use of LFUD with and without NPWT and in combination with other methods of debridement is recommended.

## References

1. Panuncialman J & Falanga V. The science of wound bed preparation. *Surg Clin N Am* 2009; 611–626.
2. Schultz GS, Sibbald RG, Falanga V *et al.* Wound bed preparation: A systematic approach to wound management. *Wound Repair Regen* 2003; 11(Suppl 1):S1–28.
3. Sibbald R G, Goodman L, Woo KY *et al.* Special considerations in wound bed preparation 2011: An update. *Adv Skin Wound Care* 2011 Sept; 415–436.
4. Sibbald RG, Orsted H, Schultz G, Coutts P & Keast D. Preparing the wound bed: Focus on infection and inflammation. *Ostomy Wound Manag* 2003; 49(11):24–51.
5. Smith F, Dryburgh N, Donaldson J & Mitchell M. Debridement for surgical wounds. *Cochrane Database Syst Rev*, The Cochrane Collaboration, 2011. John Wiley & Sons Ltd. Edinburgh Napier University.
6. [www.medicaledu.com/debridhp](http://www.medicaledu.com/debridhp) Accessed 22 October 2012.
7. Carville K. *Wound Care Manual*. 5th edn. Australia: Silver Chain Foundation, 2007.
8. Caliano C, Cobb M, Davis K *et al.* *Wound Care an Incredibly Visual Pocket Guide*. Philadelphia: Lippincott Williams & Wilkins, 2010.
9. Lewis R, Whiting P, ter Reit G, O'Meara S & Glanville J. A rapid systematic review of the clinical effectiveness and cost effectiveness of debriding

agents in treating surgical wounds healing by secondary intention. York: NHS Centre for Reviews and Dissemination, 2000.

10. Ayello EA & Cuddigan JE. Debridement: Controlling the necrotic/cellular burden. *Adv Skin Wound Care* 2004; 17(2):66–78.
11. Baharestani M. The clinical relevance of debridement. In: Baharestani M, Gottrup F, Holstein P & Vanscheidt W (eds). *The clinical relevance of debridement*. Berlin: Springer-Verlag, 1999, pp. 1–15.
12. Guy H & Grothier L. Using negative pressure therapy in wound healing. *Nurs Times* 2012; 108(36):16–20.
13. HealthPACT Review S000014. Health Scanning Technology Prioritising Summary. Low frequency ultrasound debridement. Australian and New Zealand Horizon Scanning Network (February 2007).
14. Medi-Group Australia, <http://www.medigroup.com.au/LFUD> Accessed 25 September 2012.
15. Breuing KH, Bayer L, Newalder MA & Dennis PO. Early experience using low frequency ultrasound in chronic wounds. *Ann Plast Surg* 2005; 55(2):183–187.
16. Peschen M, Weichenthal M, Schopf E & Vanschiedt W. Low frequency ultrasound treatment of chronic venous leg ulcers in an outpatient therapy. *Acta Derm Venerol* 1997; 77:311–314.
17. Ennis WJ, Formann P, Mozen N, Massey J, Conner-Kerr T & Meneses P. Ultrasound therapy for recalcitrant diabetic foot ulcers: Results of a randomised, double-blind, controlled, multicenter study. *Ostomy Wound Manag* 2005; 51(8):24–39.
18. Tan J, Abisi S, Smith A & Burnand KG. A painless Method of Ultrasonically Assisted Debridement of Chronic Leg Ulcers: A Pilot Study. *Eur J Vasc Endovasc* 2007; 33:234–238.
19. Weichenthal M, Mohr P, Stegmann W & Breitbart EW. Low-frequency ultrasound treatment of chronic venous ulcers. *Wound Repair Regen* 1997; 5(1):18–22.
20. Hiermer R, Degreef H, Vranckx JJ, Garmyn M, Massage P & van Brussel M. Skin grafting and wound healing – the dermato-plastic team approach. *Clin Dermatol* 2005; (3):343–352.

independence  
AUSTRALIA

Wound care supplies from  
simple dressings to complex  
bandaging systems, lotions &  
nutritional supplements

- Over 12,000 health care products
- Purchase by the packet or as an individual item
- Order via the website, fax, phone or email

For fast delivery all over Australia call  
Independence Australia today

T 1300 788 855 F 1300 788 811  
E [customerservice@independenceaustralia.com](mailto:customerservice@independenceaustralia.com)  
[www.independenceaustralia.com](http://www.independenceaustralia.com)