

# Management of a complex abdominal wound: a case study

Tay AC & Ong CE

## Abstract

The management of complex abdominal dehiscence can be most challenging, especially when the challenge is compounded by a need to manage high fistulae output. This case study outlines the innovative management of a complex abdominal wound in a 56-year-old Chinese female. The patient had multiple surgeries and suffered from a deep abdominal wound dehiscence. The wound was complicated by heavy exudates and contamination from faecal discharge and urine. This paper describes an innovative approach in managing this complex wound, which resulted in good outcomes for the patient.

*Keywords: abdominal wound, contamination of wound, complex wound.*

## Introduction

Management of complex abdominal dehiscence is arduous, especially when complicated by single or multiple fistulae. The prime goal is to contain corrosive faecal effluent or urine and protect the surrounding skin<sup>1</sup>. The following case study describes an innovative approach by the authors in managing a patient who, following multiple surgical procedures, subsequently developed wound dehiscence and faecal and urinary fistulae.

## Case report

A 56-year-old Chinese female was first diagnosed with stage IIIc ovarian cancer in 2001. In the same year, she underwent total hysterectomy and bilateral salpingo-oophorectomy. Her histology results showed bilateral ovarian poorly

differentiated endometrioid carcinoma with metastasis to the perimetrium, left cornual myometrium and omental fat, with extensive carcinomatous peritonei, and gastrocolic node negative. She was also treated with chemotherapy and a repeat computerised tomography scan two months later showed small hypodense focus in the right hepatic lobe near the dome of liver.

In late 2008, a positron emission tomography scan revealed metastases in the serosal and peritoneal region. The patient subsequently underwent a laparotomy, peritonectomy, anterior resection, right hemicolectomy, cholecystectomy, omentectomy, bilateral T6 ureteric stenting intraperitoneal chemotherapy and creation of double-barrel stoma to protect the new anastomosis. Standard care of her stoma was rendered after the operation.

However, upon removal of staples on the 12th postoperative day, the patient developed a deep abdominal wound dehiscence, for which she received an exploratory laparotomy washout and application of a tension suture. The patient was then referred to the wound nurse clinician for joint wound consultation with the enterostomal therapist on the 17th postoperative day when the wound defect enlarged and the tension suture started to give way. Subsequently the patient developed large amounts of clots in the peritoneal cavity, a large defect in the bladder and two perforations in the small bowel serosa. There was copious drainage from the abdominal wall, bladder and the wound edges.

The patient then underwent a third operation (in December 2008) which involved repair of the bowel and bladder

**Tay Ai Choo** \* RN, BHSc, Cert Wound Specialist  
Senior Nurse Clinician, Singapore General Hospital  
Email [tay.ai.choo@sgh.com.sg](mailto:tay.ai.choo@sgh.com.sg)  
Tel (65) 91133049

**Ong Choo Eng** RN, BNsg, ET  
Senior Nurse Clinician, Singapore General Hospital

\* Corresponding author

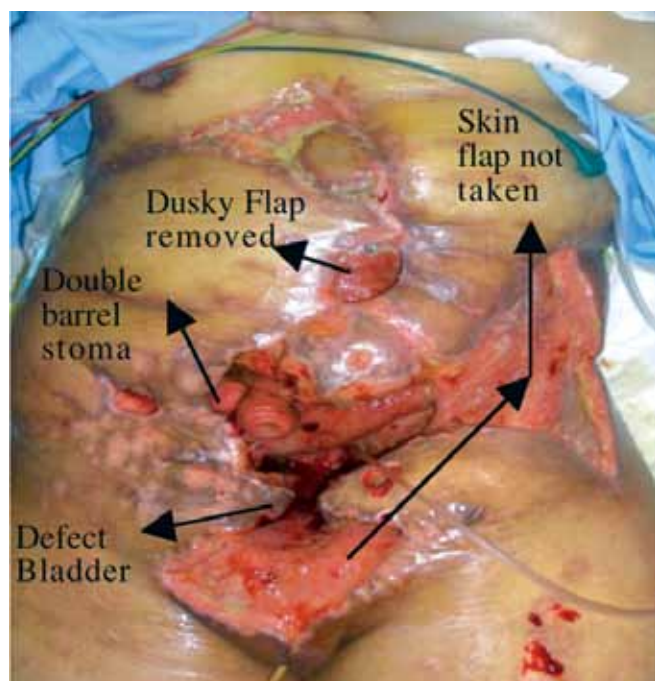


Figure 1. Appearance of complex abdominal wound at 26th postoperative day.

defect, and construction of a left dorsi flap and right rectus abdominis flap. Intraoperative findings included a small hole over the small bowel close to the pelvis and adjacent to the hole in the bladder and a 1 cm perforation at the dome of the bladder. Postoperatively, the patient was fasted to rest the bowel and was commenced on total parental nutrition. The extensive abdominal wound was jointly managed by the wound nurse clinician and enterostomal therapist during this period.

On the 26th postoperative day (Figure 1), the patient underwent her fourth surgical intervention in January 2009, as the distal two-thirds of the left dorsi flap and distal 6 cm of rectus abdominis flap were deemed significantly compromised. The compromised portions of the flap were resected and a cutaneous flap was rotated from her right abdominal and thoracic wall to cover the abdominal defect. The patient was again brought to the operating theatre for the fifth time 15 days later for debridement of left lateral dorsi donor site wound and abdominal wound. A mucous fistula was also identified at the seven o'clock position of the margin of the enterostoma (Figure 1). Large amounts of urine, bile and haemoserous exudate continued to drain into the wound bed.

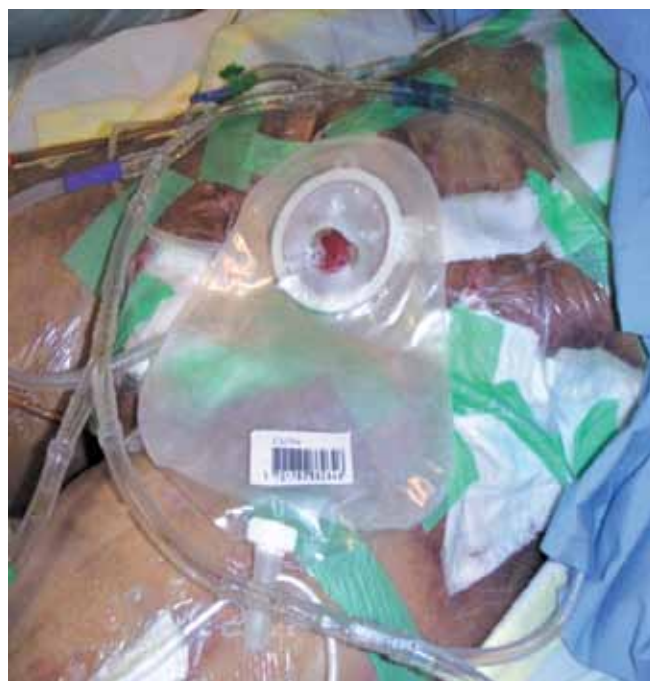

Figure 2. Use of foam cavity filler at base of wound cavity and gauze at surface as interface for negative pressure suction.

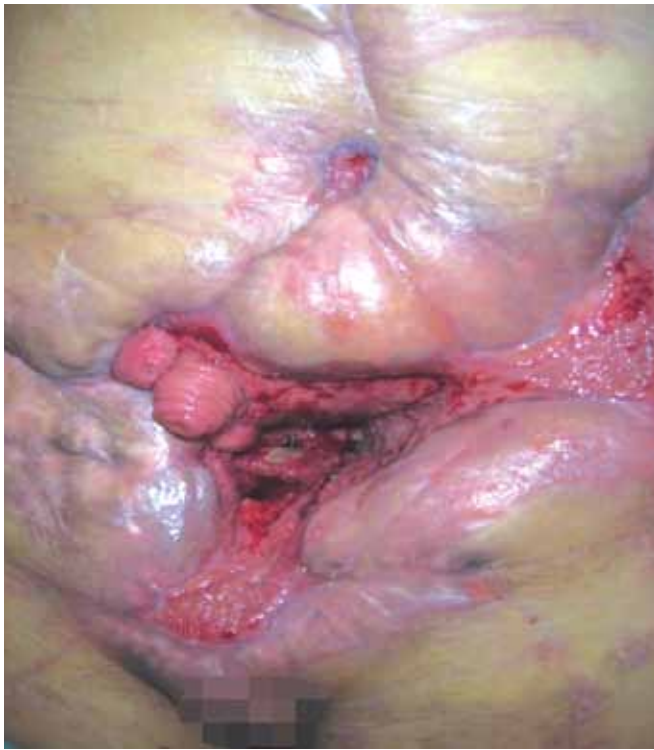### Wound management technique

The wound management goals were to isolate faecal and urinary fistula output, contain abdominal exudate and protect the peri-wound skin from maceration.

The wound and peri-wound skin were cleansed with warm normal saline 0.9% and excess normal saline was drained from the wound.. Foam cavity filler dressings and four



Figure 3. Suction system.



suction catheters (Nelaton FG14) were inserted into the cavity. The ulcerated peri-wound tissue was dressed with calcium alginate dressings and covered with gauze and film dressings. Gauze was also used to pack the wound bed, in order to create a 'snug' dressing between the wound bed and the surrounding skin edge. A film dressing was then placed over the whole area to create an air-tight seal (Figure 2). Using Y connectors, all catheters were then connected to tubing and connected to continuous wall suction at 120 mmHg (Figure 3).

The retracted ileostomy was managed using a convex base plate and a drainable pouch. A one-piece paediatric urostomy pouch was used to drain fluid from the mucous fistula on the right side. The procedure was performed by the wound nurse clinician and the enterostomal therapist and took three hours. However, the dressing only needed to be changed every 48 hours. As the wound progressed, suction catheters were gradually removed and ongoing dressings comprised foam cavity fillers and the surface wound was dressed with alginate and gauze dressings.

## Outcomes

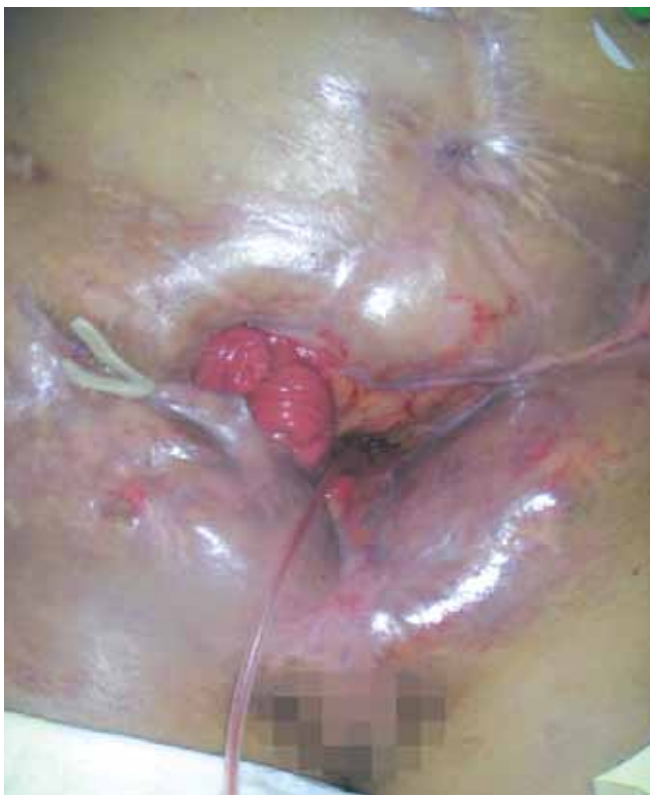By March 2009, the wound had contracted significantly and there was tremendous improvement in the surrounding skin (Figures 4 and 5). Despite the presence of a massive wound, the management system allowed the patient to sit out of bed, ambulant and undergo physiotherapy sessions. The dressings were stated to be comfortable and the patient was even able to consume her favourite food. Her pain was also well controlled. The wound continued to heal until the patient passed away due to natural progression of the disease. However, her quality of life was much improved as a result of this innovative approach to the management of a complex draining wound<sup>2</sup>.

## References

1. Beitz J, Caldwell D. Abdominal wound with enterocutaneous fistula: a case study. *JWOC Nsg* 1998; 25(2): 102-106.
2. Jones EG, Harbit M. Management of an ileostomy and mucous fistula located in a dehiscid wound in a patient with morbid obesity. *JWOC Nsg* 2003; 30(6): 351-356.

## Acknowledgement

All photos used with patient consent.



*Figures 4 and 5. The wound had contracted and the surrounding skin has made tremendous improvement and the skin was kept intact throughout the healing phase. The leakage from the bladder defect and ileostomy was well contained. The mucous fistulae have closed.*