

Client concordance and wound healing using the BodyFlow™ electrostimulation device: case series

Miller C, McGuiness B, Woodward M & Boo E

ABSTRACT

Although compression therapy is a recommended treatment for people with venous leg ulceration, concordance rates with compression therapy are lower than ideal. There are many and varied reasons for non-concordance with compression therapy. It is unclear whether the non-concordance is specific to compression therapy and whether alternative treatments may be a viable means of facilitating venous return and wound healing. Electric stimulation is one means of facilitating circulation, and Bodyflow™ Therapy is a TGA-registered portable electric stimulation device that has been shown to facilitate lymphoedema management, venous velocity and blood flow. Three case studies were undertaken with people with leg ulcers of primarily venous aetiology who were using no compression therapy or low compression therapy to assess adherence to the Bodyflow™ Therapy and wound progress. The case series found that concordance with the electrical stimulation treatment was achieved although none to the recommended schedule and with variation observed between and within clients. The treatment was well accepted by clients. Positive healing trends were observed for two of the three case studies. A single, blinded randomised controlled trial (RCT) pilot study will commence in 2014 to further appraise the clinical effectiveness and client concordance with electrical stimulation therapy for people with venous leg ulcers.

Keywords: concordance, compression therapy, wound healing, venous leg ulcer, electric stimulation.

Charne Miller*

BA(Hons), GradDip(Stat)
Research Fellow, La Trobe University Alfred Health
Clinical School, Level 4, The Alfred Centre, 99
Commercial Road, Prahran, Vic 3181, Australia
Email C.Miller@latrobe.edu.au
Tel 0421 047 911

Bill McGuiness

DipT, BEd, MNS, PhD, RN
Head of School, School of Nursing and Midwifery, La
Trobe University, Vic, Australia

Associate Professor Michael Woodward

MB, BS, MD, FRACP
Director Wound Management Clinic and Aged Care
Research, Austin Health, Heidelberg, Vic, Australia

Ellaine Boo

BN, BAsC, CritCareGradDip(ED)
Undergraduate Lecturer, School of Nursing and
Midwifery, La Trobe University, Vic, Australia

*Corresponding author

INTRODUCTION

The most recent Australian and New Zealand clinical guidelines for the prevention and management of venous leg ulcers recommend the application of compression therapy to promote wound healing for clients given no known contraindications¹. The guidelines also encourage the use of higher pressure compression compared to lower pressure, and the use of some compression rather than none; a finding that is consistent with a number of systematic reviews examining the relative clinical effectiveness of various compression products and systems^{2,3}.

Compression therapy may be a recommended standard; however, its translation to clinical care has been fraught. Reviews of adherence to compression therapy have identified considerable variability in rates of adherence in randomised controlled trial (RCT) studies (ranging 2–42% non-adherence) and evaluations of adherence in practice (10–80% non-adherence)^{4,5}. The focus of most of the studies included in these reviews examined adherence to compression stockings rather than multi-layer bandaging. In an Australian study, adherence to four-layer compression bandaging following an e-learning education program increased significantly from 13.6% to 42.3% following the training⁶. Despite the inroads achieved, there remained almost one-third of clients at the end of the study using either low compression or no compression at all.

Achieving adherence to compression therapy is paramount to optimising the speed with which a wound will heal and to prevent its recurrence, with emerging evidence suggesting that people who did not adhere to a moderate or high compression stocking following healing were nine times more likely to experience an ulcer recurrence compared to clients who did adhere⁷.

A number of factors have been identified that obstruct the implementation of compression therapy in clinical care. These factors include clinician knowledge, skills and beliefs^{4,8-11}, a range of psychosocial factors amongst clients such as self-efficacy and depression^{12,13}, wound size and depth¹⁴, and client knowledge, aesthetics factors, and capacity to physically tolerate and apply and remove compression products, and cost^{4,8,9}.

In short, the barriers to achieving concordance with compression therapy are numerous. Yet, aside from rectifying the venous insufficiency through venous surgery, compression therapy remains the current treatment of choice during healing and maintenance. What other factors can improve the prognosis for the proportion of people who do not tolerate compression therapy, to avoid a prolonged wounded episode and frequent recurrence? This answer is dependent on whether the complex psychosocial factors shaping concordance with compression are specific to compression therapy? Would concordance to alternative treatments differ? If so, could healing be improved and recurrence avoided in instances where concordance with compression therapy has not been achieved? Whilst alternative treatments to compression generally are not yet supported by published evidence, there may be an alternative where compression is not tolerated or complied with.

ELECTRICAL STIMULATION

Electrical stimulation¹⁵ has been examined in wound healing for a diverse range of wound aetiologies. Concepts of the ‘current of injury’ and ‘current of healing’¹⁶⁻¹⁸ have generated a variety of dressing products and therapies designed to transmit an electric field to the wound bed that will facilitate healing. Electrical stimulation can also be used in wound healing to stimulate muscles and improve circulation, addressing issues common in wound management such as oedema, lymphoedema, and venous hypertension. It is this latter application of electrical stimulation that is examined further by this paper.

Evidence for the uses of electrical stimulation in promoting improved circulation via muscle stimulation has emerged from the fields of physiotherapy and sports science. Electrical stimulation therapy has been used to improve systemic and peripheral circulation¹⁹ and muscle recovery and blood return to the heart after exercise when used in combination with passive foot movements²⁰. The therapy further reduced the risk of people developing deep vein thrombosis and lung embolism^{21,22} and hastened muscle recovery after ligament surgery²¹.

Electrostimulation therapy, in comparison to a standard exercise program, resulted in fewer amputations and improved oxygen delivery to the leg when used to treat patients who had already experienced a

lower limb amputation due to arterial circulation disturbances²³. Electrical stimulation facilitated the restoration of musculoskeletal, sensory and anatomical functions for people following spinal cord injury²⁴. The treatment was well tolerated and improved muscle strength among people with chronic obstructive pulmonary disease who had poor exercise tolerance²⁵.

An electric stimulation therapy — Bodyflow™ Therapy (Figure 1) — involves the application of electrodes to the individual limb that deliver a mild transdermal electrical stimulus targeting stimulation of smooth muscle (Tunica media) to promote the stimulation of arterial, venous and lymphatic systems. Unlike other electrotherapy devices, the Bodyflow™ Therapy has a set frequency between one and two Hertz, which is exclusively patented to Bodyflow™. The frequency is promoted as targeting the smooth muscle to optimally address issues such as oedema whilst other modalities target striated muscle stimulation.

The Bodyflow™ electrostimulation device is a small, portable device suitable for self-administration in the home setting. Users require brief instruction on the operation of the device. It is recommended that the Bodyflow™ Therapy is used four times daily for 20-minute sessions. Electrodes are attached to the lower limb around the wound and not directly over it. The device is pre-set to a single, non-adjustable, specific low frequency found between one and two Hertz, a current that specifically targets smooth muscle. Use of the device can create a pulsing or tingling sensation. The therapy has approval with the Australian Therapeutic Goods Administration (TGA) as a Class IIa 35046 Stimulator, electrical, soft tissue. Registered applications include circulation increase in venous and blood flow and swelling oedema reduction. The therapy is registered with Medibank Private.



Figure 1: The portable BodyFlow™ electrostimulation device

The Bodyflow™ electrostimulation device has been used in combination with class II compression garments to reduce leg lymphoedema in a double-blind clinical trial²⁶ with healthy subject research supporting claims that Bodyflow™ increases venous velocity and blood flow²⁷ and decreased muscle damage and inflammation following exercise-induced muscle damage²⁸.

Thus, some promising results have been published regarding both the Bodyflow® Therapy and electrical stimulation more generally that suggest electrical stimulation can support the clearance of blood and other fluids such as lymph and interstitial fluids from the lower limb. Thus, the treatment can target the principal physiological failure underpinning venous disease. In circumstances where there is poor

concordance with compression therapy due to pain or discomfort, unacceptable aesthetics, the impact on bathing, footwear or mobility, or due to difficulty donning or doffing compression stockings, an alternative such as electrical stimulation may facilitate venous return and be a more easily accommodated treatment.

In 2013, two Melbourne-based wound clinics trialled the Bodyflow™ electrostimulation device. The goal of the case series was to assess the feasibility of clients self-administering the Bodyflow™ Therapy in the home environment, describe adherence to the Bodyflow™ Therapy, and describe clinical outcomes associated with the use of Bodyflow™ Therapy including the impact on wound healing as well as the incidence of adverse events. Of principal interest was whether clients using no compression therapy at all or low compression therapy, would adhere to and achieve some clinical benefit from the Bodyflow™ Therapy.

METHOD

Clients approached to participate in the study had an existing leg ulcer of primarily venous aetiology. All had been recommended to use moderate to high compression therapy, but were using either no compression or low compression (≤18 mmHg). Contraindications for the use of the Bodyflow™ Therapy include an existing deep vein

thrombosis, the presence of an implanted cardiac device such as a permanent pacemaker or internal defibrillator, pregnant women, and people diagnosed with an active malignant disease, and as such clients were excluded if they presented with one or more contraindications. Finally, any person with an existing cognitive impairment or the absence of carer support that would impair the capacity for the person to safely use the Bodyflow™ device were excluded from consideration as a case study.

Three case studies were undertaken. Clients all provided their verbal consent to use the Bodyflow™ electrostimulation devices, to receive training in the use of the device from a representative from Bodyflow™, and to have information from their health record used in a case study. Verbal consent was documented in the client’s health record. Information used in the case studies was limited to data routinely gathered during the course of wound consultations at the two clinics. As such, submission to a Human Research Ethics Committee was not required. The Bodyflow™ electrostimulation devices were provided free of charge for use in these case studies by the manufacturer. No funding was received to conduct the case series and the case studies were written independent of the product manufacturer.

In the battle against biofilms, IODOSORB[◇] gets the job done.



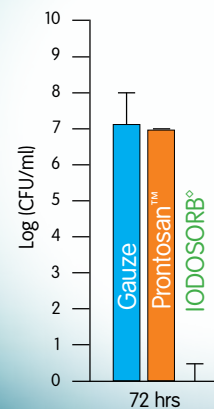
- Following debridement, biofilms can return in as little as 3 days without active intervention.¹
- In a recent study, IODOSORB[◇] was the only topical dressing capable of completely killing biofilm bacteria.²
- The significantly improved efficacy provided by IODOSORB[◇] may be attributed to the CADEXOMER iodine formulation which results in a sustained release that maintains iodine availability.²

IODOSORB[◇] – powered by CADEXOMER.

Indicated for the treatment and healing of chronic ulcers.

Australia: T 13 13 60 www.smith-nephew.com.au/healthcare
 New Zealand: T 0800 807 663 www.smith-nephew.com/nz

Bacterial biofilm detected after 72hrs²



(Graph adapted from ref. 2)

References 1. Wolcott RD, et al. Biofilm maturity studies indicate sharp debridement opens a time-dependent therapeutic window. *J Wound Care* 2010; 19: 320-328.
 2. Phillips PL, et al. Antimicrobial dressing efficacy against mature *Pseudomonas aeruginosa* biofilm on porcine skin explants. *Int Wound J* 2013; doi:10.1111/iwj.12142.

© Smith & Nephew. Trademark of Smith & Nephew SNI1042 (10/13)

RESULTS

Case Study 1

Mrs E was 62 years of age when first presenting for care at a nurse-led vascular wound clinic. Mrs E was referred to the clinic in June 2012 for treatment of an ulcer on her medial right lower leg. She was diagnosed as having hypertension, hypercholesterolaemia, and arthritis. Her health status was complicated by obesity. She had a bilateral knee replacement and total left hip joint replacement. Her medication regimen on admission was atorvastatin, perindopril, telmisartan, meloxicam, paracetamol, and oxymorphone immediate-release (PRN). Mrs E lived with her husband, was engaged in full-time employment, and was assessed as being independent on all activities of daily living, although she was ambulating with supports.

An arterial scan revealed normal blood flow and a pedal pulse was detected. The wound was considered to be venous in origin. Mrs E agreed to use Comprilan short-stretch compression. Factors influencing the choice of compression for this client included Mrs E's decreased flexibility to apply compression garments due to spinal fusion and cosmetics of the stocking with her daily garments. Wound care education was provided at clinic visits.

In December 2012, the original wound had healed; however, a new pressure-related injury had developed on the right lateral ankle. In late January 2013, a new wound developed on the tibial aspect of the left leg, measuring 2 cm². The wound bed contained yellow/green slough tissue. Surrounding tissue was pink, extending for 3 cm around the wound. The surrounding skin had a normal temperature. The wound itself had minimal exudate. Treatment involved manuka honey foam dressing and tubular form compression. The right lateral ankle injury remained present, measuring 0.5 cm in diameter and with fragile, painful edges. There was nil strikethrough and Elastoplast® was in situ.

Four weeks later (Figure Mrs E #1), while improvements to the periwound region were noted and epithelial tissue was present, the wound had marginally increased in size to 2.5 cm² and oedema was present. The right lateral ankle ulcer was unchanged in size, although pain had decreased since night offloading was implemented. Given challenges for the health care team to implement a moderate to high compression therapy treatment regimen and the limited progress that was observed for wound healing, Mrs E commenced treatment using the Bodyflow™ electrostimulation device on both legs. The

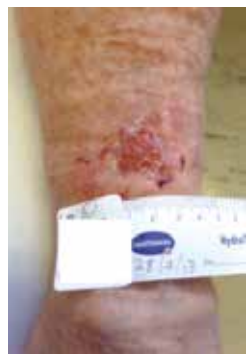

Figure Mrs E #1 28 March 2013

recommended treatment schedule involved four daily sessions of 20 minutes' duration. The client was shown how to implement the treatment and provided with a unit for use in her home. Mrs E was encouraged to continue using tubular form compression at times other than when implementing the Bodyflow™ treatment.

A review of Mrs E wounds was conducted one week after commencing the Bodyflow™ treatment (4 April 2013). Mrs E reported implementing the Bodyflow™ treatment three times daily and using tubular form compression in between Bodyflow™ treatments. The leg appeared less oedematous although baseline measures were not available to quantify the change, and subsequent measures of the calf circumference revealed no further change. The wound size on the left leg was reduced to 1.75 cm², wound margins were progressing and there was evidence of epithelisation (Figure Mrs E #2). There was decreased serous exudate, minimal periwound inflammation, and Mrs E reported decreased pain at the wound site. There was evidence of petechial bleeding bilaterally at the site of the gel patches. Anticoagulant therapy or diagnosis of a bleeding disorder was excluded. Adhesive removal wipes were subsequently used to facilitate the removal of the Bodyflow™ electrodes. Treatment continued with the Bodyflow™ device, the wound was dressed with a viscopaste patch and an absorbent pad in place, and two layers of tubular form compression. The wound on the right ankle had a dry scab approximately 1–2 mm in diameter; there was nil indication of inflammation or report of pain.

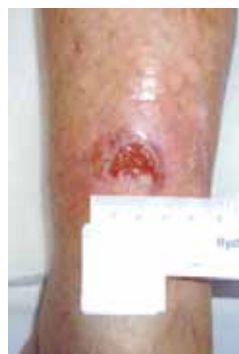

Figure Mrs E #2 4 April 2013

The wound/limb status was unchanged one week later (11 April 2013) although the petechial bleeding on the calf area was reduced. Five weeks after commencing the Bodyflow™ treatment, the left leg wound measured 1.1 cm² and had granular tissue developed to the epidermal layer (Figure Mrs E #3). There was minimal exudate. Bodyflow™ was continued to assist with oedema management. Biatain® foam was used to dress the wound and two layers of tubular compression continued. The right ankle had total intact skin integrity. Pressure offloading in bed and two-layer compression was continued.

Almost one year (23 May 2013) after Mrs E's first presentation to the clinic and four months following the development of the ulcer on the left tibial area, Mrs E had bilaterally healed legs (Figure Mrs E #4). Intact skin integrity and nil oedema were observed for both legs.

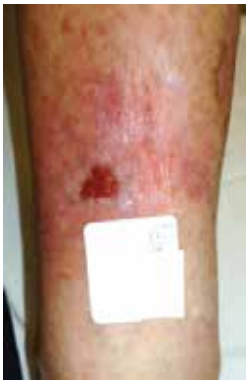

Figure Mrs E #3 2 May 2013

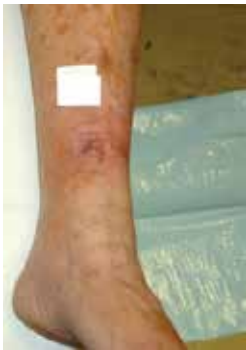

Figure Mrs E #4 23 May 2013

Bodyflow™ treatment was ceased. Education was provided regarding ongoing compression use and pressure-reduction measures. A review by a vascular consultant was obtained and no surgical intervention was recommended.

Mrs J

Mrs J first presented to a GP-led wound clinic in metropolitan Melbourne in December 2009 with bilateral leg wounds. At the time of first attending the clinic, she was 54 years old and living in independent housing with her husband. She was from an English-speaking, non-Indigenous background. She had limited mobility and required a frame to ambulate. She received a disability pension.

At the time of referral, she was diagnosed with diabetes, asthma, COAD, anaemia, lymphoedema, Hodgkin’s lymphoma (in remission), depression, bilateral carpal tunnel syndrome, and had a thyroidectomy. Mrs J was morbidly obese, weighing 158 kilograms at the time of assessment. Mrs J’s medication regimen included 14 different medications, including paracetamol/codeine, venlafaxine, frusemide, metformin, and thyroxine.

Mrs J had ulcers on the posterior gaiter region of both legs that were reported to have begun 19 months ago. The left ulcer measured 25 cm² and the right ulcer was 28 cm². As a *Pseudomonas* infection was suspected, antibiotic therapy was commenced. Mrs J had an ABPI of 1.33, indicating likely incompressible vessels. Mrs J was at this time admitted to hospital for wound care that included intravenous antibiotics. Dressing selection included an antimicrobial

and an absorbent secondary dressing. Mrs J was unable to tolerate compression therapy.

Over the next three years, a variety of treatments were trialled to facilitate the management and healing of Mrs J’s leg ulcers, reduce the oedema, and reduce pain. During this time, the wounds received frequent debridement using the Sonoca® low frequency ultrasound debridement system used in the wound clinic²⁹. Dressings were poorly tolerated by Mrs J and an antimicrobial dressing was used only when infection was present. Mrs J was referred to a pain clinic, and education and supports were provided to facilitate weight loss and improve her diabetes management. Her suitability for hyperbaric oxygen therapy was assessed but ultimately was not pursued. Mrs J trialled pneumatic compression and although she reported that the oedema was improved, pain was experienced during treatments. This pneumatic compression was nevertheless encouraged for several years, but infrequently used. The wound clinic continued to see Mrs J with additional care provided in her home by district nurses.

At a wound clinic visit on 4 April 2013 use of the Bodyflow™ Therapy was discussed with Mrs J. At this visit tracings were not attended due to wound pain. The client history provides wound progress notes on 24 January 2013 at which time the wound dimensions were 90 cm² and 62 cm² for the right and left ulcers respectively and wound tissue was predominately yellow in colour. Surrounding skin was dry/scaly and inflamed. There was heavy and serous exudate, mild odour, and continuous pain was reported. Mrs J’s weight had decreased to 115.2 kilograms on 18 March 2013.

Bodyflow™ Therapy was commenced on 12 April 2013. Mrs J and her husband were provided education on how to use the machine. At this



Figure Mrs J #1: left leg 12 April 2013

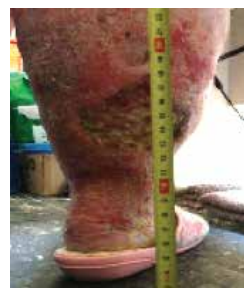

Figure Mrs J #2: right leg 12 April 2013

time a 20-minute Bodyflow™ treatment was provided and there were no initial complaints or irritable symptoms. Images of the wounds were taken in the home at the time of education regarding the use of the Bodyflow™ device (Figure Mrs J #1 and Mrs J #2).

On 27 April 2013 the client reported using the Bodyflow™ treatment an average of twice daily and using the treatment for longer to compensate for fewer treatment sessions. The electrodes, if ill placed, were causing Mrs J discomfort but when well placed, were tolerated. Mrs J reported increased 'wound weeping' on a daily basis. On 9 May 2013 the ulcer dimensions were 41 cm² and 35 cm² for the right and left ulcers respectively (Figures Mrs J #3 and #4). Wound tissue remained predominately yellow, exudate was heavy and serous, a mild odour was documented, and surrounding skin was macerated and dry/scaly.

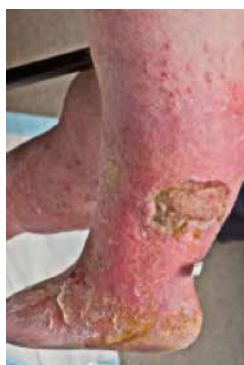

Figure Mrs J #3: left leg 9 May 2013

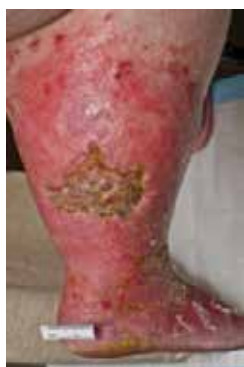

Figure Mrs J #4: right leg 9 May 2013

Subsequent to the clinic visit in May 2013, Mrs J decreased her use of the Bodyflow™ Therapy to approximately four sessions per week for the next month, and to approximately one session per week during June 2013. This underutilisation was the patient's choice and was not due to any adverse effects of the treatment. She was encouraged repeatedly to use the treatment as recommended. Wound measurements attended on 6 June 2013 and 4 July 2013 nonetheless reflect reductions in the ulcer size: 32 cm² and 29 cm² for the left and right wound respectively in June, and 18 cm² and 22 cm² for the left and right wound respectively in July.

Throughout the remainder of July and August 2013, Mrs J used the Bodyflow™ Therapy an average of two sessions per week with the duration of the session anywhere between 20 and 60 minutes. Images of Mrs J's next wound clinic visit on 8 August 2013 were available (Figures Mrs J #5 and #6) and wound tracings attended in early September (5 September 2013) suggest the wounds were progressing well towards healing; the ulcers measuring 15 cm² and 13 cm² for the left and right ulcers respectively.

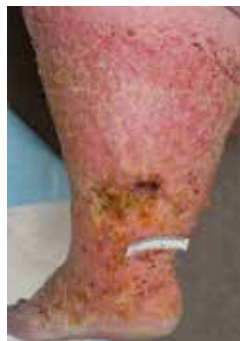

Figure Mrs J #5: left leg 8 August 2013

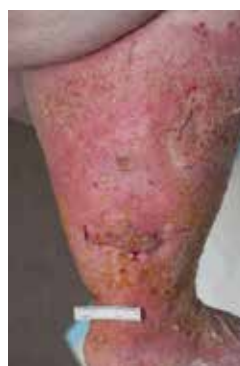

Figure Mrs J #6: right leg 8 August 2013

Mrs J was not seen back in the clinic for the remainder of the 2013 year due to absences and the development of a foot infection in late November that saw her hospitalised at the time of her next scheduled appointment. She reported to the clinic that her ulcers, prior to the development of the foot infection, were almost completely healed but had now started to 'seep' again. She also reported that in the latter stages she had been able to increase her concordance with the Bodyflow™ Therapy to twice daily.

Mrs M

Mrs M was referred to a GP-led wound clinic in metropolitan Melbourne in 2010. Mrs M was 81 years of age at referral. She was English-speaking and came from a non-Indigenous background. She was a widower residing in independent living accommodation. She had a history of osteoarthritis, hypertension, transient ischaemic attacks, cellulitis, and a deep venous thrombosis had been queried. Mrs M was overweight. Allergies to penicillin and cephalosporins were recorded.

She had bilateral wounds that had been present for approximately four weeks. She had an ABPI of 0.94 and the wounds were considered to be of venous aetiology but an arterial component was considered possible. Over subsequent years the ulcers intermittently progressed and then relapsed, never achieving full closure. She continued to be seen in the wound clinic with additional wound care provided in home by district nurses. Mrs M tolerated two layers of tubular elastic stocking (Tubigrip™) for compression therapy. At the time of commencing the Bodyflow™ Therapy she was using a silver antimicrobial dressing and an absorbent secondary dressing (Zetuvit®).

On 6 June 2013, Mrs M was provided training on how to use the Bodyflow™ device for use on her left leg only. Additional training was provided on 8 July 2013 as the device had become non-operational because it was not being charged properly. Subsequently, Mrs M was able to self-manage the Bodyflow™ treatments. She reported using the Bodyflow™ Therapy twice daily and for longer durations to compensate for less frequent than recommended treatment sessions. She had no complaints and no complications were reported from the use of the Bodyflow™ Therapy. She continued to use two-layer Tubigrip.

Wound tracings attended on 20 June 2013 and prior to commencing the Bodyflow™ treatment provide ulcer measurements of the left

lateral posterior (21 cm²) (Figure Mrs M#1) and left medial (9 cm²). Wound tissue was red and yellow, surrounding skin was dry/scaly, and serous and heavy exudate was documented. The wounds were odorous and caused her continuous pain. As wound infection was suspected, a swab was taken and appropriate antibiotics commenced.

As noted, commencement of Bodyflow™ Therapy was delayed. Wound tracings attended four days after commencing Bodyflow™ Therapy indicated a greatly increased wound surface area for the left lateral posterior wound (41 cm²); a review of clinical photos and tracings showing some islands within the wounds had connected. There was no change to the medial ulcer.

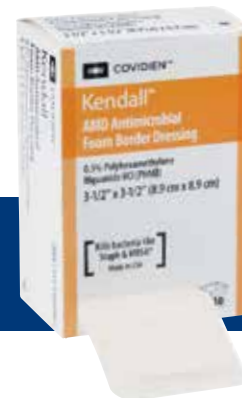Mrs M reported continued to use Bodyflow™ Therapy twice daily for 20-minute treatment sessions in addition to two-layer Tubigrip for five months from July to November 2013, at which point monitoring for the case study was ceased. During this time Mrs M attended the clinic for monthly visits.

The status of Mrs M's left lateral posterior ulcer continued to fluctuate during her use of Bodyflow™ Therapy while the left medial ulcer remained largely unchanged. Wound tracings revealed wound surface area dimensions for the left lateral posterior ulcer ranging from 67 cm² in August 2013, decreasing to 51 cm² in October 2013 before



What if you tried something different?

Kendall™ AMD Antimicrobial Foam Dressings with PHMB
Engineered for performance and comfort



Wound care needs choice.
Try a proven innovation with PHMB¹⁻⁴

References:

1. Sibbald RG, Coutts P, Woo KY. Reduction of bacterial burden and pain in chronic wounds using a new polyhexamethylene biguanide antimicrobial foam dressing – clinical trial results. *Adv Skin Wound Care* 2011; 24(2): 78–84.
2. Ciprandi G. Palliative wound care in pediatric patients. 21st Conference of the European Wound Management Association, EWMA 25–27 May 2011.
3. Warriner L, Spruce P. Managing overgranulation tissue around gastrostomy sites. *Br J Nurs* 2012; Suppl 21(5): S20–25.
4. Johnson S and Leak K. Evaluating a dressing impregnated with polyhexamethylene biguanide. *Wounds UK* 2011; 7(2): 20–25.

COVIDIEN PTY LTD, 166 EPPING ROAD, LANE COVE NSW 2066 AUSTRALIA (T) 1800 252 467

COVIDIEN, COVIDIEN with logo, Covidien logo and positive results for life are U.S. and internationally registered trademarks of Covidien AG. Other brands are trademarks of a Covidien company. © 2014 Covidien AG or its affiliate. All rights reserved. WC 183-05-14



increasing in size again at the November assessment 74 cm² (Figure Mrs M #2). At this last visit the wound tissue was yellow in appearance and a green discharge noted. A *Staphylococcus* and *Pseudomonas* infection were subsequently confirmed. Antibiotics were prescribed to treat the infection.

For Mrs M, the characteristic fluctuation in wound size and periods of infection observed over the three–four years she had had her wounds was unchanged, despite consistent but less than recommended routine use of Bodyflow™ Therapy.

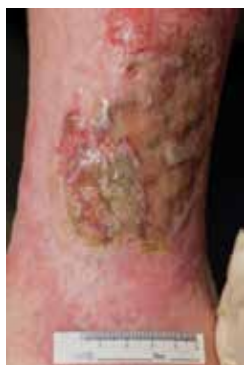

Figure Mrs M #1 20 June 2013

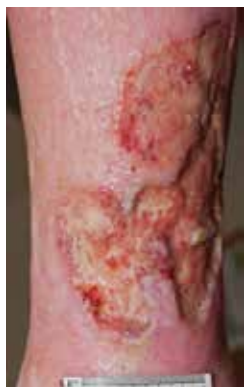

Figure Mrs M #2 28 November 2013

DISCUSSION

Three case studies were conducted to examine concordance and the clinical outcomes associated with the Bodyflow™ Therapy. The case series specifically explored the application of the Bodyflow™ Therapy in instances of non-concordance with moderate to high compression therapy to determine if a clinically effective alternative was viable for this client group.

The goal of the study was not to supersede or undermine the importance of ensuring that clinicians are skilled in the assessment of a client's suitability for or application of compression therapy, or that all clients should receive the strongest recommendation and education regarding the use of as much compression as is tolerable.

Clients participating in this case series were encouraged to continue or commence the use of compression therapy.

The case series findings have a number of implications. First, the concordance observed with the Bodyflow™ Therapy suggests it is a viable treatment option for clients who find it difficult to tolerate moderate to high compression therapy. However, like the challenges in achieving concordance with compression therapy, none of the clients in this study were able to adhere to the recommended schedule of Bodyflow™ treatments and variation between and within clients experience were observed. These case studies are limited by the amount of information both sought and recorded about concordance and the reasons the four sessions of 20 minutes were not implemented by any of the case studies. Nonetheless, the authors regarded the capacity for clients to self-manage the treatments at home and to adhere to the treatment at all as one of the major questions to be addressed by the case series. In a health field where clinicians campaign tirelessly to optimise the time and amount of compression therapy being used, the use of the Bodyflow™ device in these case studies has been considered promising. It is suggested that the treatment is a feasible option for this client cohort because all three patients were able to be taught and administer the therapy in their own home. Minimal difficulties or discomfort were reported in relation to implementing the machine.

In the absence of a control group, it cannot be assumed that the electric stimulation therapy caused the healing trajectories observed. Rather, this case series suggests that wound healing and oedema management was observed concurrently with Bodyflow™ treatment for two case studies, with ongoing wound size fluctuations observed with the third case study. Monitoring for the case series was concluded in the 2013 calendar year, at which time only one client had achieved complete wound healing, one was close to healing, and another had ulcers that had increased in size. Overall, these results were regarded as positive by the clinical teams at the two wound clinics given the longevity of these wound episodes and the challenges experienced in achieving concordance with compression therapy. For the third case (Mrs M), infection may have been a factor explaining the suboptimal response to the electrical stimulation therapy. The outcomes were assessed as being sufficiently promising to merit further controlled research enquiry regarding the clinical effectiveness of the electrical stimulation treatment.

The use of the device aligned with its Australian and international product registration and the product had existing applications in physiotherapy and lymphoedema management, and as such the treatment was considered to be safe at the outset. Nonetheless, the case series provides further endorsement that the device did not elicit significant adverse events. Petechial bleeding was associated with gel patches in the case study of Mrs E and was resolved with the use of adhesive removal wipes. Mrs J reported that if the electrodes were poorly placed they caused discomfort but none when positioned correctly. Client acceptability of the treatment was good.

One of the clients in the case series had previously trialled and subsequently not adhered to intermittent pneumatic compression; another product that would appear to be an opportunity for use

by people who had been unable to tolerate compression garments. Therefore, it is interesting to note that studies of intermittent pneumatic compression³⁰ have tended to compare intermittent pneumatic compression with moderate to high compression³¹, thus assessing the clinical effectiveness of the treatment rather than concordance.

The conduct of case studies within clinical practice in the absence of a Human Research Ethics Committee submission and approval made it necessary to rely upon information collected as part of usual care. As a consequence, these case studies were able to make only limited conclusions about the impact of the Bodyflow™ Therapy on measures of oedema and lymphoedema such as limb volume as these did not form part of the wound clinics' usual progress record. More precise evaluation of these and other indicators would be important inclusions in future research.

An intriguing consideration emerges from this case series regarding the psychosocial nature of non-adherence to treatment. That is, is non-concordance with treatment best understood as a person-specific issue, as one that is specific to the intervention, or a combination of both? Whilst more efficacy-based research is required to substantiate any treatment as an alternative to compression therapy, examining the nature of non-concordance will further the knowledge and capacity clinicians have to facilitate client engagement with treatment choices known to heal wounds and prevent their recurrence.

A single-blinded RCT pilot study will commence in 2014 to enable further appraisal of the clinical effectiveness and client concordance with electric stimulation therapy. The results from this study will, if a positive outcome is observed, support the design of a large clinical trial. The ultimate purpose of this line of enquiry is to explore the viability of one adjunct treatment modality for use by the wound management field to avoid and resolve chronic leg ulceration.

CONCLUSION

This research suggests that concordance with Bodyflow™ Therapy is practicable by people who have not previously been able to tolerate moderate to high compression therapy and positive healing trends were observed for two of the three case studies. Adherence to compression therapy is a critical foci for the health care team⁷. In the absence of concordance with compression therapy, the capacity to achieve concordance with alternative treatments that have been designed to deliver comparable physiological effects is an important area for further exploration. The literature regarding electrical stimulation generally and this case series specifically suggests that this treatment could offer a simple and non-invasive means of supporting venous return and facilitating timely healing outcomes.

Key points:

- Compression therapy is not tolerated by some people with a venous leg ulcer.
- Electrical stimulation therapy has been shown to facilitate lymphoedema management, venous velocity and blood flow.
- The case series found concordance with electrical stimulation therapy was achieved, although less than the recommended treatment schedule.
- The therapy was well tolerated.
- Promising wound healing outcomes were observed with the use of electrical stimulation therapy in two of the three case studies.
- Alternative therapies that will facilitate venous return merit exploration where compression therapy cannot be tolerated.

BrightSky
AUSTRALIA

specialist healthcare products at your door

To find out more:

- ☎ 1300 88 66 01
- @ info@brightsky.com.au
- 🌐 www.brightsky.com.au

Australia's leading supplier supporting wound care

- One-stop-shop for traditional and advanced wound care
- Extensive range of products and brands in stock
- Flexible and reliable delivery service Australia-wide
- Order in small or large quantities
- Clinical expertise, tools and the BeBright Study Series for healthcare professionals

REFERENCES

1. The Australian Wound Management Association Inc and the New Zealand Wound Care Society Inc. The Australian and New Zealand Clinical Practice Guideline for Prevention and Management of Venous Leg Ulcers Australia: Cambridge Publishing; 2011 [21/06/2013]. Available from: http://www.awma.com.au/publications/2011_awma_vlug.pdf
2. O'Meara S, Cullum N, Nelson E & Dumville J. Compression for venous leg ulcers. *Cochrane Database Syst Rev* 2012.
3. O'Meara S, Tierney J, Cullum N *et al*. Four layer bandage compared with short stretch bandage for venous leg ulcers: systematic review and meta-analysis of randomised controlled trials with data from individual patients. *BMJ* 2009; 388:b1344.
4. Moffatt C, Kommala D, Dourdin N & Choe Y. Venous leg ulcers: patient concordance with compression therapy and its impact on healing and prevention of recurrence. *Int Wound J* 2009; 6(5):386–93.
5. Van Hecke A, Grypdonck M & Defloor T. Interventions to enhance patient compliance with leg ulcer treatment: a review of the literature. *J Clin Nurs* 2007; 17:29–39.
6. Kapp S, Miller C, Sayers V & Donohue L. The Leg Ulcer Prevention Program: effectiveness of a multimedia client education package for people with venous leg ulcers. *Wound Practice & Research* 2010; 18(2):80–90.
7. Kapp S, Miller C & Donohue L. The clinical effectiveness of two compression stocking treatments on venous leg ulcer recurrence: a randomised controlled trial. *Int J Low Extrem Wounds* 2013; DOI: 10.1177/1534734613502034.
8. Annells M, O'Neill J & Flowers C. Compression bandaging for venous leg ulcers: the essentialness of a willing patient. *J Clin Nurs* 2008; 17(3):350–9.
9. Field H. Fear of the known? District nurses' practice of compression bandaging. *Wound Care* 2004; 9(12):S6,S8,S10–1.
10. Flanagan M, Fletcher J, Rotchell L, Schofield J & Thomson S. The provision of leg ulcer services by practice nurses. *Nurs Stand* 2000; 14(54–60).
11. French L. Community nurse use of Doppler ultrasound in leg ulcer assessment. *Br J Comm Nurs* 2005; 10(9):S6–S15.
12. Finlayson K, Edwards H & Courtney M. The impact of psychosocial factors on adherence to compression therapy to prevent recurrence of venous leg ulcers. *J Clin Nurs* 2010; 19:1289–97.
13. Miller C, Kapp S & Donohue L. Examining factors that influence the adoption of health-promoting behaviours among people with venous disease. *Int Wound J* 2012.
14. Miller C, Kapp S, Newall N *et al*. Predicting concordance with multi-layer compression bandaging. *J Wound Care* 2011; 20(3):101–12.
15. Kloth LC & McCulloch JM. Promotion of wound healing with electrical stimulation. *Adv Wound Care* 1996; 9(5):42.
16. Cutting K. Electric stimulation in the treatment of chronic wounds. *Wounds UK* 2006; 2(1):9.
17. Keith M. Electric stimulation of chronic wounds. *J Comm Nurs* 2007; 21(1):18.
18. Ramadan A, Elsaidy M & Zyada R. Effect of low-intensity direct current on the healing of chronic wounds: a literature review. *J Wound Care* 2008; 17(7):292–6.
19. Glasser RM. Functional neuromuscular stimulation. Exercise conditioning of spinal cord injured patients. *Int J Sports Med* 1994; 15(3):142–48.
20. Grunovas A, Silinskas V, Poderys J & Trinkunas E. Peripheral and systemic circulation after local dynamic exercise and recovery using passive foot movement and electrostimulation. *J Sports Med Phys Fitness* 2007; 47(3):9.
21. Faghri P, Votto J & Hovorka C. Venous hemodynamics of the lower extremities in response to electrical stimulation. *Arch Phys Med Rehabil* 1998; 79(7):842–8.
22. Kaplan R, Czynri J, Fung T, Unsworth J & Hirsh J. Electrical foot stimulation and implications for the prevention of venous thromboembolic disease. *Thromb Haemost* 2002; 88:200–4.
23. Presern-Strukelj M & Poredos P. The influence of electrostimulation on the circulation of the remaining leg in patients with one-sided amputation. *Angiology* 2002; 53(3):329–35.
24. Faghri P & Trumbower R. Clinical Applications of Electrical Stimulation for Individuals with Spinal Cord Injury. *Clinical Kinesiology* 2005; 59(4):48–62.
25. Bourjeily-Habr G, Rochester CL, Palermo F, Snyder P & Mohsenin V. Randomised controlled trial of transcutaneous electrical muscle stimulation of the lower extremities in patients with chronic obstructive pulmonary disease. *Thorax* 2002; 57(12):1045–9.
26. Piller N, Douglass J, Heidenreich B & Moseley A. Placebo controlled trial of mild electrical stimulation. *J Lymphoedema* 2010; 5(1):15–25.
27. Parsi K, Exner T, Connor D, Whittaker S, Joseph J, Ma D, editors. Blood Flow, Fibrinolysis and Anti-Procoagulant Activity After Treatment with a Portable Electrostimulation Device (Bodyflow™) in Healthy Subjects. The Australian College of Phlebology; 2007; Sydney, Australia.
28. Sostaric S, Pearce A, Gatt B, McKenna M, Stathis C & Goodman C, editors. Effects of mild electro-stimulation (Bodyflow™) treatment on healthy humans following exercise induced muscle damage. Indianapolis, USA: American College of Sports Medicine Conference; 2008.
29. Shannon MK, Williams A & Bloomer M. Low-frequency ultrasound debridement (Sonoca-185) in acute wound management: A case study. *Wound Practice & Research* 2012; 20(4):200–205
30. Partsch H. Intermittent pneumatic compression in immobile patients. *Int Wound J* 2008; 5:389–97.
31. Nelson E, Mani R, Thomas K & Vowden K. Intermittent Pneumatic compression for treating venous leg ulcers. *Cochrane Database Syst Rev* 2011.