

Skin manifestations with COVID-19: the purple skin and toes that you are seeing may not be deep tissue pressure injury

ABSTRACT

Many reports are occurring concerning areas of purpuric/purple skin and purple toe lesions in patients diagnosed with COVID-19 (SARS-CoV-2) (Figure 1). Wound care providers are being asked if these skin lesions are forms of Deep Tissue Pressure Injury and/or “skin failure”. Early reports of COVID-19 related skin changes included rashes, acral areas of erythema with vesicles or pustules (pseudo-chilblain), other vesicular eruptions, urticarial lesions, maculopapular eruptions, and livedo or necrosis.¹⁻⁴ The pattern and presentation of skin manifestations with COVID-19 is more than rashes. The purpose of this paper is to guide the wound care clinician in determining if the “purple skin” being seen is a deep tissue pressure injury or a cutaneous manifestation of COVID-19.

Keywords COVID-19, purple skin, deep tissue pressure injury

For referencing Black J and Cuddigan J. Skin manifestations with COVID-19: the purple skin and toes that you are seeing may not be deep tissue pressure injury. WCET® Journal 2020;40(2):18-21

DOI <https://doi.org/10.33235/wcet.40.2.18-21>

BACKGROUND

The true incidence of COVID-19 related skin injury is unknown at this time; however, NPIAP board members practicing in COVID-19 hotspots and others who are submitting inquiries to the NPIAP Website are reporting purple discoloration of the skin and soft tissue not exposed to pressure. One form is being referred to as a novel phenomenon called “COVID toes” (i.e. deep red or purple appearance of the toes). Clinicians are requesting guidance from NPIAP regarding the differential diagnosis of these injuries from pressure injuries.

LITERATURE REVIEW

Acute respiratory failure and a systemic coagulopathy are critical aspects of the morbidity and mortality seen with

severe acute respiratory distress syndrome-associated with coronavirus-2 (SARS-CoV-2).⁵ Early in the COVID-19 pandemic, it appeared that the primary risk of death from the disease was severe pneumonia followed by a cytokine storm. While much of the pathogenesis of the corona viruses is unknown, there are increasing cases of complications due to hypercoagulation and microvascular occlusion including stroke and pulmonary embolism.⁶⁻⁷ This accelerated clotting process appears to also involve the skin.

COVID-19 enters cells via the angiotensin converting enzyme 2 (ACE2) receptors, which are broadly expressed in vascular endothelium, respiratory epithelium, alveolar monocytes, and macrophages.⁸ Later in the disease course, COVID-19 replicates in the lower respiratory tract, and generates a secondary viremia, followed by extensive attack against target organs that express ACE2, such as the heart, kidneys, gastrointestinal tract, and vast distal vasculature. This process of viral spreading correlates with the clinical deterioration, mainly taking place around the second week following disease onset.

Magro and colleagues⁵ reported on five cases with an exceptionally high proportion of aberrant coagulation in severe cases of critically ill adult patients with COVID-19. Their COVID-19 patients exhibited a hypercoagulable state, featuring prolonged prothrombin time, elevated levels of D-dimer and fibrinogen, and near normal activated partial thromboplastin

Joyce Black

PhD, RN CWCN, FAAN
University of Nebraska Medical Center

Joyce Cuddigan*

PhD, RN, FAAN
University of Nebraska Medical Center on behalf of the National
Pressure Injury Advisory Panel
Email jcuddiga@unmc.edu

*Corresponding author

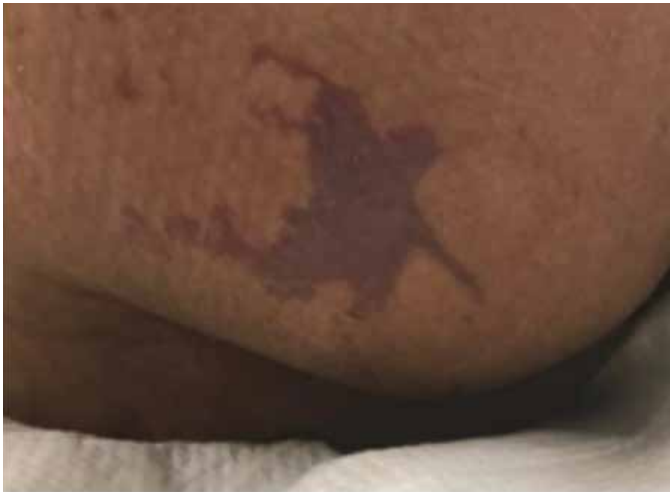

Figure 1 right buttock on day 1

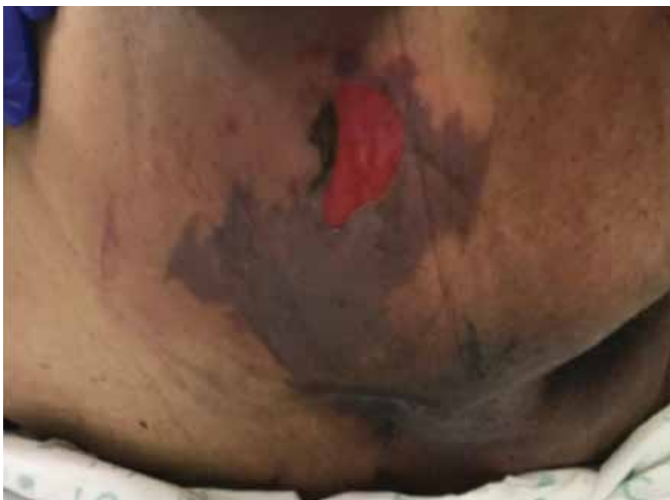

Figure 1 right buttock, sacrum and coccyx on day 3. Photos used with permission of Beaumont Health, Royal Oak MI

time. Two patients progressed to overt disseminated intravascular coagulation (DIC). DIC has been described before; Tang et al.⁹ reported that 71.4% of non-survivors and 0.6% of survivors of COVID-19 showed evidence of overt DIC.

Two of the cases with biopsy results from Magro's⁵ work are presented here with permission of the author and publisher. They examined skin and lung tissues from five patients with severe COVID-19 characterised by respiratory failure (n=5) and purpuric skin rash (n=3). The purpuric skin lesions showed a pauci-inflammatory thrombogenic vasculopathy, with deposition of Complement 5b-9 and Complement 4d in both grossly involved and normally appearing skin. A pattern of tissue damage consistent with complement-mediated microvascular injury was noted in the lung and/or skin of the five individuals with severe COVID-19. One of the three patients with skin change had a lacey, livedoid rash on the lower extremities; it is not included in this paper.

CASES

Case 1

A 32-year-old male with a medical history of obesity-associated sleep apnea and anabolic steroid use, currently taking testosterone, presented with a 1-week history of fever and cough. He became progressively more dyspneic with fevers to 40°C, ultimately becoming ventilator dependent from acute respiratory failure. Chest x-ray showed bilateral airspace opacities. He had an elevated d-dimer of 1024ng/ml (normal range 0-229) on presentation, which peaked at 2090ng/ml on hospital day 19, and a persistently elevated INR of 1.6-1.9, but a normal PTT and platelet count. Serum complement levels were elevated for CH50 at 177 CAE Units (normal range 60-144), C4 of 42.6 mg/dL (normal range 12-36), and high normal range for C3 at 178 mg/dL (normal range 90-180 mg/dL). Over this patient's continuing three-plus weeks on ventilator support he completed courses of hydroxychloroquine and azithromycin, followed by the experimental anti-CoV agent remdesivir (5mg/kg IV daily for 10 days).

After only four days on ventilator support, retiform purpura with extensive surrounding inflammation was noted on his buttocks (Fig. 2 A). Skin biopsy showed a striking thrombogenic vasculopathy accompanied by extensive necrosis of the epidermis and adnexal structures, including the eccrine coil (Fig 2b). There was a significant degree of interstitial and perivascular neutrophilia with prominent leukocytoclasia. IHC showed striking and extensive deposition of C5b-9 within the microvasculature (Fig. 2C).

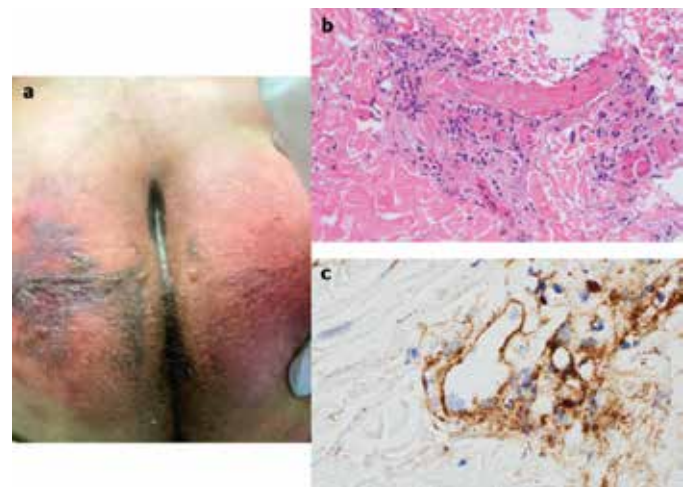


Figure 2

Case 2

A 66-year-old female, with no significant past medical history, was brought to the ED after nine days of fever, cough, diarrhea, and chest pain. She was hypoxemic, with diffuse bilateral patchy airspace opacities, without effusions, on chest x-ray. She was admitted and treated with hydroxychloroquine and prophylactic anticoagulation with enoxaparin. Three days later she became confused, increasingly hypoxemic with rising serum creatinine levels and was intubated. Renal replacement was initiated. On hospital day 10, thrombocytopenia (platelets

128 × 10⁹/L) and a markedly elevated d-dimer of 7030ng/ml, but normal INR and PTT, were noted. The next day dusky purpuric patches appeared on her palms and soles bilaterally (Fig. 3 A). A skin biopsy of one lesion showed superficial vascular ectasia and an occlusive arterial thrombus within the deeper reticular dermis in the absence of inflammation (Fig. 3B). Extensive vascular deposits of C5b-9 (Fig. 3C), C3d, and C4d (Fig. 3D) were observed throughout the dermis, with marked deposition in an occluded artery. A biopsy of normal-appearing deltoid skin also showed conspicuous microvascular deposits of C5b-9 (Fig. 3E). Sedative infusions were discontinued that day, unmasking a comatose state. Computerised tomographic imaging of the head revealed multifocal supra- and infratentorial infarctions, with complete infarction of the area supplied by the left middle cerebral artery.

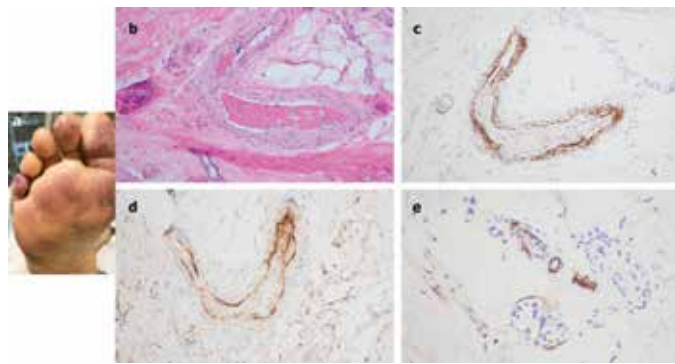


Figure 3

The skin lesions have multiple appearances and patterns associated with microvascular occlusion of vessels in the skin. Some skin lesions can appear with a livedoid or lace-like pattern most commonly on the extremities and others can be more purpuric in nature. Rarely, patients have the appearance of purpura fulminans and frank necrosis or skin infarct. Purpura fulminans is a rare but life-threatening disorder, characterised by hemorrhagic infarction of the skin caused by disseminated intravascular coagulation and dermal vascular thrombosis. This disturbance has traditionally been cited to develop from bacterial endotoxin (typically meningococcus) and mediated by various factors, including the inflammatory cytokines interleukins, interferon and tumor necrosis factor-alpha and consumption of natural anticoagulants. Purpura fulminans has more than 50% mortality from multiple organ dysfunction syndrome.¹⁰

From the data available now, at least a subset of sustained, severe COVID-19 may define a type of catastrophic microvascular injury syndrome mediated by activation of complement pathways and an associated procoagulant state.

Clinical guidance for differentiating these injuries from pressure injuries

Purple areas on non-pressure loaded surfaces lack a pressure-shear etiology and should not be classified as pressure injuries. They may resemble purpura fulminans which is consistent with the histopathology noted above and has been reported

in other systemic infections. They may also resemble other dermatological conditions associated with microvascular injury and thrombosis such as retiform purpura, livedo reticularis and cutaneous vasculitis.

Purple areas on pressure loaded surfaces (whether prone or supine) require further investigation. Deeper soft tissue may also be damaged because of pressure-shear, particularly in the buttocks, sacrum and coccyx when positioned supine or on the face, knees, and other high-risk body parts when positioned prone. We would recommend that discolored areas on any body surface subjected to pressure loading or shear be palpated to detect differences in tissue consistency and temperature to rule out concomitant deep tissue pressure injury. Theoretically, the same COVID-19 related vascular changes may be occurring in underlying soft tissue (e.g., muscle), rendering those tissues less tolerant of the damaging effects of pressure and shear. The histological specimens presented in the above case studies show clotting. Histological specimens of deep tissue pressure injuries showed frank necrosis of skin, fat, and muscle.¹¹ The histological appearance of Deep Tissue Pressure Injury (DTPI) is not the same as the COVID-19 skin changes.

COVID toes: A deep red appearance may be due to vascular inflammation. A deep purple appearance may be indicative of microthrombi. Patients receiving vasopressors may also develop purple toes; however this is a result of vasoconstriction and ischemia. *In the absence of pressure and/or shear, these injuries should not be diagnosed as pressure injuries.*

Summary

The purpuric or non-blanchable purple skin lesions seen with COVID-19 are not consistent with DTPI, because they lack pressure induced injury to underlying soft tissue cells and the skin changes likely represent tissue ischemia due to clotting. High risk patients who have been immobile, hypotensive, and hypoxic are at high risk for developing deep tissue pressure injury, however these pressure injuries would be seen on pressure bearing skin and soft tissue. While the term, purpura fulminans, may be correct, other terms have been proposed for this phenomena such as retiform purpura, livedo reticularis and cutaneous vasculitis. Further study is required before the pathophysiologic link of COVID-19 to purpura and other cutaneous manifestations can be fully elucidated. After confirming that the skin change is not due to pressure, wound care providers should not label these skin changes as DTPI, but rather potential skin manifestations from COVID-19.

Research continues to evolve on the entire disease state of COVID-19. Wound care clinicians can aid in the completeness of these investigations by bringing the changes in the skin to the attention of those researchers to understand the pathophysiology. Treatments of these skin-related conditions have also to date not been investigated. In order to enhance our understanding of COVID-19 skin manifestations, consider submitting case reports to the American Academy of Dermatology COVID-19 Dermatology Registry at <https://www.aad.org/member/practice/coronavirus/registry>.¹²

REFERENCES

1. Bouaziz JD et al. Vascular Skin Symptoms in COVID-19: A French Observational Study. *J Eur Acad Dermatol Venereol*. 2020 Apr 27. <https://doi.org/10.1111/jdv.16544>. Online ahead of print.
2. Guan WJ et al. Clinical Characteristics of Coronavirus Disease 2019 in China. *N Engl J Med*, 2020 Apr 30;382(18):1708-1720. doi: 10.1056/NEJMoa2002032. Epub 2020 Feb 28.
3. Recalcati S. Cutaneous Manifestations in COVID-19: A First Perspective. 2020 Mar 26. *J Eur Acad Dermatol Venereol*. doi: 10.1111/jdv.16387. Online ahead of print.
4. Galván Casas C, Català A, Carretero Hernández G, et al. Classification of the cutaneous manifestations of COVID-19: a rapid prospective nationwide consensus study in Spain with 375 cases. *Br J Dermatol*. 2020.
5. Magro C, Mulvey JJ, Berlin D, Nuovo G, Salvatore S, Harp J, Baxter-Stoltzfus A, Laurence J. Complement associated microvascular injury and thrombosis in the pathogenesis of severe COVID-19 infection: A report of five cases. *Transl Res*. 2020 Apr 15. <https://doi.org/10.1016/j.trsl.2020.04.007> [Epub ahead of print]
6. Oxley, TJ et al. Large-Vessel Stroke as a Presenting Feature of Covid-19 in the Young. *New Eng J Med* April 28, 2020. doi: 10.1056/NEJMc2009787
7. Poissy J. et al. Pulmonary Embolism in COVID-19 Patients: Awareness of an Increased Prevalence. *Circulation*. 24 Apr 2020. doi: 10.1161/circulationaha.120.047430.
8. Cao W and Li T. COVID-19: towards understanding of pathogenesis. *Cell Res* 30, 367–369 (2020). <https://doi.org/10.1038/s41422-020-0327-4>.
9. Tang N et al. Abnormal coagulation parameters are associated with poor prognosis in patients with novel coronavirus pneumonia. *J Thromb Haemost*. 2020. doi: 10.1111/jth.14768.
10. Betrosian AP, Berlet T, Agarwal B. Purpura Fulminans in Sepsis. *J Med Sciences* 332 (6) 2006, 339-345.
11. Edsberg L et al. (2018, March 2) Histology of Deep Tissue Pressure Injury: What can be learned from cadavers. National Pressure Ulcer Advisory Panel Conference, Las Vegas NV.
12. American Academy of Dermatology (2020, May 12). COVID-19 Dermatology Registry. <https://www.aad.org/member/practice/coronavirus/registry>.

This NPIAP White Paper is intended for wide public distribution. Please share with your contacts who may benefit from this information. This content (unless otherwise specified) is copyrighted to the NPIAP

ACKNOWLEDGEMENTS

The NPIAP gratefully acknowledges the contributions of the following individuals.

Authors: Dr Joyce Black, University of Nebraska Medical Center; Dr. Janet Cuddigan, University of Nebraska Medical Center on behalf of the National Pressure Injury Advisory Panel.

CONFLICT OF INTEREST

The authors declare no conflicts of interest.

FUNDING

The authors received no funding for this study.

REVIEWERS

This White Paper was reviewed by the NPIAP Board of Directors. Feedback on content was provided by Dr Virginia Capasso, Massachusetts General Hospital; Dr Jill Cox, Rutgers University; Dr Barbara Delmore, NYU Langone Health; Dr William Padula, The Leonard D. Schaeffer Center for Health Policy & Economics, University of Southern California; Dr Joyce Pittman, University of Southern Alabama; Dr Lee Ruotsi, Saratoga Hospital Medical Group – Wound Healing; Dr Sharon Sonenblum, Georgia Institute of Technology; and Dr Ann Tescher, Mayo Clinic.

CONSULTATION AND GUIDANCE

NPIAP appreciates the guidance provided by Dr Ashley Wysong Chairman of the Department of Dermatology at the University of Nebraska Medical Center and Dr Laura Edsberg, Director of the Center for Wound Healing Research at Daemen College in Amherst NY.

CASE STUDIES AND FIGURES

Figures 2 and 3 used with permission of Dr Jeffrey Laurence of Cornell University. Elsevier, the publisher, grants permission to make all its COVID-19-related research that is available on the COVID-19 resource centre - rights for unrestricted research re-use and analyses in any form or by any means with acknowledgement of the original source.

Photos in Figure 1 were used with permission of Beaumont Health, Royal Oak MI.