

# A review of severe lower limb trauma with extensive soft tissue loss and subsequent reconstructive surgery: its impact on the lymphatic system

Malou van Zanten, Neil Piller & James Finkemeyer

## ABSTRACT

Lymphoedema is the accumulation of fluid in the tissues. Higher cytokine levels within this fluid can cause chronic inflammation, which leads to poor tissue health and repair. As lymphatic failure progresses, lymphoedema worsens, resulting in visible swelling and mobility issues. These issues are associated with discomfort, heaviness and pain. Lymphoedema is more commonly recognised as secondary to cancer and its treatment; however, it can also occur after trauma with extensive soft tissue damage or loss. Severe open fractures due to high-energy trauma require soft tissue reconstruction with local, regional or free tissue in addition to the fixation of bony injury. Oedema, both within and surrounding the reconstructed site, can present acutely in the post-surgery setting. However, in some patients the swelling fails to resolve and the patient develops chronic oedema. This is lymphoedema, when the lymphatic system is in a state of failure, either due to its inability to regenerate in the wounded area or its inability to handle the increased load imposed in the post-traumatic period. Findings in this literature review show no current best practice protocols are available at this stage of traumatic lower limb lymphoedema. However, new lymphatic imaging techniques focused on lymphatic function may provide a better understanding of lymphatic failure, possibly identifying the reasons for poor regrowth and inosculation of lymphatic channels, or the effect of increased loads on the existing system. This literature review is in preparation for a clinical study.

*Keywords: Lymphoedema, lower limb trauma, reconstruction, lymphatic regeneration, lymphatic imaging.*

### Ms Malou van Zanten\*

BSc Health, MSc Candidate

Lymphoedema Research Unit, Level 3, Department of Surgery, Flinders Medical Centre, Flinders University of South Australia, Bedford Park, SA 5042

Email malou.vanzanten@flinders.edu.au

### Professor Neil Piller

BScHons, PhD

Lymphoedema Research Unit, Level 3, Department of Surgery, Flinders Medical Centre, Flinders University of South Australia, Bedford Park, SA 5042

Email neil.piller@flinders.edu.au

### Dr James Finkemeyer

BBiomedSci, BMBS

Department of Plastic & Reconstructive Surgery  
Level 5, Department of Surgery, Royal Adelaide Hospital  
Adelaide, SA, 5000

Email james.finkemeyer@wh.org.au

\* Corresponding author

## THE LYMPHATIC SYSTEM

The lymphatic system is vital for tissue homeostasis and relies on the tentative balance between the entry of lymphatic fluid from tissue and the ability of the system to transfer that fluid centrally. The lymphatic system consists of a deep system, the lymph collectors, and a superficial system, the lymph pre-collectors and capillaries. These two systems are separated by the deep fascia. In the event of deep system failure, fluids and their contents are re-routed via the superficial system. This re-routing, however, can be affected by induration of the fascia and of the epi-fascial tissues in general. Unlike the vascular system, the lymphatic system is not a closed circulatory system. This means lymph can be transported from distal to proximal areas, and also from the deep system to the superficial system and vice versa. A vital characteristic of the lymph capillaries is that they are highly permeable<sup>1,2</sup>. The lymphatic system is responsible for transporting proteins, fluid, macromolecules, inflammatory mediators such as cytokines, fatty acids and immunological cells which plays an important role in both the regulation of homeostasis and immune responses<sup>3</sup>. The major lymph collectors are often situated within the adventitia of large arteries and veins. Lymphatic flow in peri-arterial lymphatics is induced by the arterial pulsatile flow<sup>4</sup>. As lymphatic fluid is slowly transported through the body it enters lymph nodes.

Each lymph node acts as a filter and provides a key role in activating immunologic responses<sup>4,5</sup>.

The lymphatic capillaries and collecting vessels form a delicate system, and its interdependence with the vascular system makes it vulnerable for damage caused by surgery, mechanical trauma or infections<sup>5</sup>.

## MICROCIRCULATION

A microcirculatory lymphatic plexus is present in the superficial layers of the skin, which acts in conjunction with the vascular system to maintain tissue fluid homeostasis. These highly permeable lymph capillaries take part in the exchange of fluid, cells and macromolecules<sup>3</sup>. Much of the formed lymphatic fluid is dispersed superficially to the deep fascia, but some is further transported sub-fascially to the deeper lymphatic system. Lymphatic fluid drains from the peripheries to the abdomen where it travels along tributaries to the thoracic duct and is in turn introduced back into the venous system<sup>1,3</sup>. This process of filtration and reabsorption ensures the balance of the interstitial pressure, where volume and contents are maintained<sup>4</sup>.

## IMPAIRED MICROCIRCULATION

When filtration of the venous system exceeds the reabsorption capacity of the lymphatic system, interstitial volume homeostasis is disturbed. This is initially characterised by localised tissue oedema. Local tissue oedema can spread as nearby systems are overloaded and can cause a segment, or even the whole limb, to swell<sup>2</sup>. Additionally, the generally protein-rich fluid accumulation in the tissues can induce inflammatory reaction, leading to fibrosis development, impaired immune responses and reduced wound healing capacity<sup>3</sup>. Delivery of crucial nutrients to cells is reduced or completely stagnated, causing an overall patho-histological picture of chronic inflammation<sup>2</sup>. Contrary to previous theories, recent research suggests that the lymphatic system is responsible for 100% of the reabsorption process, and is, therefore, central to local control of superficial fluid homeostasis<sup>6,7</sup>.

## LYMPHOEDEMA

Lymphoedema is a progressive chronic condition caused by the accumulation of fluid in the body tissues. Lymphoedema can be hereditary as a primary condition, or acquired secondary to damage or disruption of lymphatic vessels; most commonly in western countries lymphoedema is seen due to malignancies and their treatment<sup>2,5,8</sup>. In this article lymphoedema due to secondary cause is the focus, since the soft tissue trauma and the subsequent surgery has damaged the lymphatic system or compromised its ability to regrow. Lymphoedema can occur following any injury in which the superficial or deep lymphatic systems are damaged by trauma. In high-energy injuries involving soft tissue in combination with bone, both systems can be profoundly injured and efforts at reconstruction are often ineffective at re-establishing lymphatic function. Soft tissue reconstruction often involves importing tissue, either locally or from a distant site, to cover exposed bony injury and re-establish the integrity of skin coverage<sup>9</sup>.

Although the vascularity of such tissue is ensured by the surgeon, there is little capacity to address lymphatic function of the tissue —

therefore, these patients are at risk of developing severe lymphoedema in the recovery period.

If the load on the compromised lymphatic system is higher than its transport capacity then the swelling will increase and result in regional or whole limb discomfort, heaviness or pain. The inevitable scar tissue formation that develops as a result of injury and subsequent surgery prevents the development of lympho-lymphatic anastomosis. Scar tissue perpendicular to lymph collectors may present blockage to lymphatic drainage pathways and subsequently cause a reduction in lymph transport<sup>1,2</sup>. There is a delicate balance, which, if disrupted, will result in the onset of lymphoedema.

In Australia, lymphoedema secondary to cancer is most often reported with an estimation of at least 20% of those who are treated for melanoma, prostate, breast or gynaecological cancer<sup>10</sup>. By best estimates, one in 30 people are affected by lymphoedema worldwide<sup>11</sup>. A firm incidence or prevalence report is almost impossible to accurately determine. Current estimates likely understate the prevalence of lymphoedema given that commonly the first stages of lymphoedema go unrecognised or are misdiagnosed. Also, there remains little conformity on specific diagnostic criteria, making inter-study comparisons difficult<sup>10,12</sup>.

Late-stage chronic lymphoedema is hallmarked by an increase of local adipocyte size and numbers and local tissue induration<sup>13</sup>. Since the local and often general, specific and non-specific defence systems are compromised when the lymphatic system fails, these patients remain prone to recurrent infections and inflammation<sup>5</sup>. Patients affected by lymphoedema not only carry the burden of physical consequences; psychosocial consequences such as distress, depression and reduced body image have been proven in previous studies<sup>2,10</sup>.

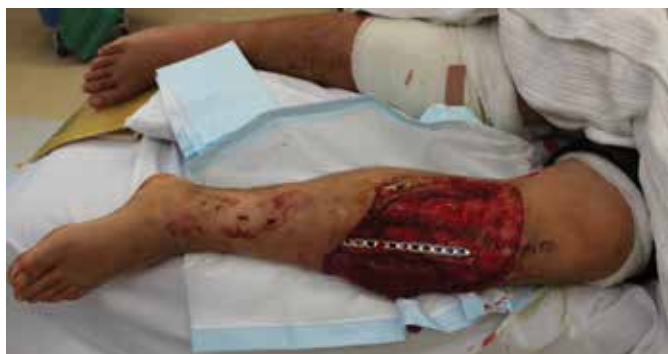Whatever the cause of the lymphoedema and whatever the region, generally the physical, social and psychological issues are similar.

## Trauma

The role of trauma in lymphoedema is less well defined than lymphoedema as a sequelae of cancer treatment. However, it is an important factor in determining the long-term impact on function and mobility following trauma.

Blunt injuries may be caused by acceleration, deceleration, compression or shearing injuries resulting in various tissue components being crushed, macerated or devitalised entirely. In Australia the majority of traumas are related to motor-vehicle collision and falls<sup>14</sup>. These injuries seem to be divided between the older people who generally have a higher incidence of falls, whereas the young and the middle aged have more transport-related injuries<sup>15,16</sup>. Such injuries result in a reduced quality of life, impaired functional outcome and large associated cost of medical care<sup>17,18</sup>.

The lower extremity contains vital long bones that are vulnerable to injury in high-energy trauma. In particular, the anatomically superficial location of the tibia means that it is less protected by fatty subcutaneous tissue or muscle and is often fractured with associated



Severe lower leg trauma with extensive soft tissue loss

soft tissue loss. The extent of the injury results in an open fracture. An open fracture is to be handled with extreme care and is a surgical emergency due to damage of not only the bone but also soft tissue, blood and lymphatic vessels at the micro and macro levels<sup>19</sup>. Open fractures are likely to be sites of mal-union and superficial infection as well as infection of the deeper (sub-fascial) and bone areas<sup>20</sup>. Fractures are the most common type of hospitalised injury and treatment requires immediate irrigation and debridement<sup>21</sup>.

In Australia, trauma is initially treated by orthopaedic surgery (66%) followed by plastic surgery (10%), neurological surgery (10%), general surgery (7%) and CTS/vascular and urology surgery (7%)<sup>22</sup>. Salvage of the lower limb is dependent on the nature of the bony injury, gross contamination leading to infection, and the extent and nature of soft tissue damage. Even after reconstruction has been achieved, an ongoing risk for deep and superficial infection with gram-positive and gram-negative pathogens remains associated with open fractures and can result in serious complications<sup>23,24</sup>.

### Soft tissue damage

While wound healing is not the focus of this article, the process of soft tissue repair is inseparably linked with the regeneration of lymphatic function. An open wound associated with a compound fracture results in a complex and acute process of repair. Acute wounds undergo an initial phase of coagulation followed by a complex inflammation cascade mediated by lymphocytes, macrophages and granulocytes<sup>25</sup>. All of these most often facilitate the healing and normalisation process, but can be sub-optimal if the lymphatic system is dysfunctional. Although lymphatic capillaries have a strong ability to regrow in healthy tissue, in damaged tissue this is more challenging<sup>26</sup>. Soft tissue trauma will disrupt microvasculature and its repair processes must come into play. Generally this means an increase in plasma filtration and lymph accumulation in the dermis along with dilated and thus sometimes dysfunctional collecting lymphatics<sup>5</sup>.

Every wound is at risk of infection, irrespective of cause, size, anatomical location and management<sup>27</sup>. When the lymphatic system is damaged and loses its immunological functionality, the risk is greatly increased<sup>28</sup>. The development of wound infection depends on

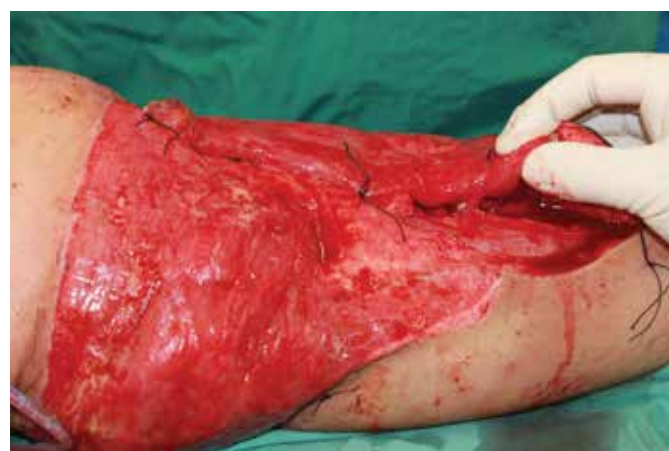the type of trauma, location of the wound, presence of contamination, adequacy of initial debridement and decontamination and the timing of reconstruction<sup>25</sup>. Open wounds with extensive soft tissue loss have a dismal healing prognosis unless properly reconstructed. By assessing the biochemical and anatomical healing processes of surgical wounds, the tissue regeneration, formation of collagen fibres and importance of vascular involvement can be reviewed<sup>25,29</sup>.

Information regarding regeneration of lymph capillaries in human wound healing and their importance is scarce. However, Nogami *et al.*<sup>30</sup> visualised lymphatic regeneration in rats, demonstrating the regrowth of lymphatic capillaries from the healthy tissue edges of the wounds. This is different from vascular regeneration that rapidly forms in the granulation phase of acute wound healing<sup>30</sup>. In general, open wounds demonstrate significant delay in lymphatic channel regeneration as in comparison with arterial and venous angiogenesis. In the soft tissue surrounding wounds there is the accumulation of waste products in the tissues which mechanically compromise lymph capillaries and micro-vascular flow, thereby increasing capillary permeability and venous after load<sup>31</sup>. This process adds considerable burden to an already damaged lymphatic system — essentially overloading an under-functioning system, leading to increased risk of failure, infection and delayed tissue healing.

Load is increased but transport capacity has been reduced so there is a high chance of failure, with infection and poor tissue healing being the major negative outcomes.

## RECONSTRUCTION AND THE LYMPHATIC SYSTEM

The treatment of compound fractures with extensive soft tissue loss depends on the overall presentation of the extent of bone, soft tissue and vascular injury and requires a multidisciplinary approach<sup>24</sup>. Therefore, there is no standard practice that can be applied to all patients. However, treatment such as immediate debridement of contaminated and devitalised tissue followed by reconstruction with either skin grafting in minor wounds or more complex muscle flaps



Free flap reconstruction (latissimus dorsi flap)

for extensive injuries are used. The so-called reconstructive ladder describes the reconstructive management based on complexity of the soft tissue defect. The reconstructive ladder starts with minor procedure such as skin grafts that are commonly used over exposed muscles, fascia or subcutaneous tissues. Local and regional flaps are harvested near the wound area, as they contain a similar blood supply. These are used for small to moderate wounds. Either a muscle flap or a fascio-cutaneous flap can be applied in various ways such as being rotated, transported or transposed into the wound<sup>21</sup>. The benefit of the muscle and fascio-cutaneous flap is the local blood supply, which is essential for healing. Free flap reconstruction is the most complex modality which is used to close large defects that are not otherwise graftable or amendable to local reconstruction. This type of flap contains tissue harvested from another area of the body containing an artery and vein which is reattached in the defect site<sup>21</sup>. This reattachment ensures tissue vascularisation, which creates an ideal tissue coverage of a healing fracture. Although it is accepted that lymphatic vessels contribute to healthy tissue<sup>31</sup>, the role of the lymphatic microcirculation and subsequent lymphatic regeneration in flap reconstruction has not been researched thoroughly. Despite being technically demanding, the success rate for free flap reconstructions has been estimated as high as 91% to 99%<sup>32</sup>. Survival is dependent on revascularisation, and is determined by monitoring the continuous arterial flow and venous outflow<sup>33</sup>. Venous outflow obstruction is seen as the main cause of free flap failure<sup>34</sup>.

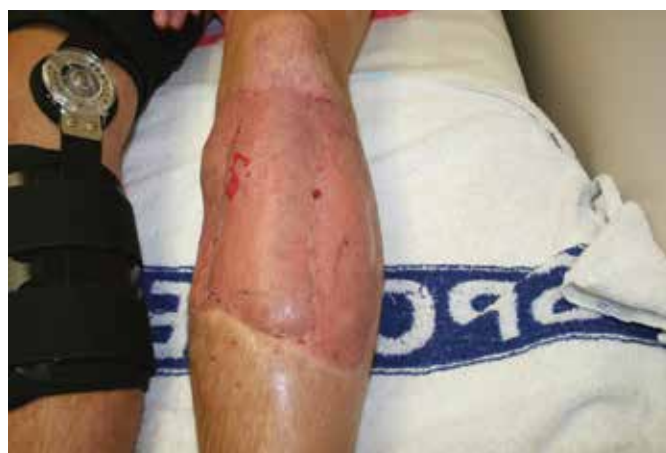Oedema that occurs in the free flap post-surgery has been identified as an impairment in lymph transport<sup>35</sup>. Khazanchi *et al.*<sup>36</sup> explored lymph transport in free flap reconstruction sites using lymphoscintigraphy. Their eight participants showed lymphatic activity in the free flap early after surgery (nine days)<sup>36</sup>. This was supported in a study by Slavin *et al.*<sup>35</sup> where they performed lymphoscintigraphy 13 days post-surgery, and found indications of advanced regeneration probably starting as early as eight days post-operatively<sup>35</sup>. Although both studies mentioned fast uptake of the radio colloid tracer and therefore excellent lymph drainage, they did not focus on any abnormal lymph node size (enlargement) or lymph collector dilation.

Persistent oedema has been observed long after the fracture and wound have healed, suggesting that lymphoedema is present<sup>37</sup>. Often there is a late diagnosis of this chronic condition and only as the clinical symptoms of lymphoedema have progressed or increased or caused immobility<sup>38</sup>. Thus, the factors that contribute to post-trauma lymphoedema should be explored so that early intervention can be initiated<sup>39</sup>.

Szczęśny *et al.*<sup>40,41</sup> explored post-traumatic oedema and found enlargement of lymph nodes in all 21 patients with post-traumatic oedema<sup>40,41</sup>. The often associated dilation of major distal lymph collectors in the entire lower extremity and its associated decrease of lymph flow has been confirmed by lymphoscintigraphy<sup>41</sup>. Of course, this adds to the problem of wound repair, healing and infection.

## OUTCOME

Interestingly, research questionnaires and research tools aimed at assessing the functional outcomes of patients following open lower limb fractures do not classify lymphoedema as a parameter of interest<sup>18,38</sup>. This is a concerning oversight that fails to acknowledge the role of a healthy lymphatic system in normal wound healing and the adverse outcomes associated with a failing lymphatic system. Lymphoedema impacts considerably on a patient's quality of life, mobility and emotional wellbeing, and leaves the injured limb with an increased risk of recurrent infection and delayed healing<sup>42</sup>. However, it is recognised that patients complain about oedema and diminished sensibility in the leg or foot, but a treatment or procedure protocol remains absent<sup>39,43</sup>. Studies of short and long-term outcomes of lower limb trauma patients show poor functional outcomes and this is of significant concern<sup>44</sup>. Correlation of poorer outcomes with lymphatic dysfunction may help to identify patients that are at risk of wound healing complications so that appropriate management can be implemented.



Healing phase of a free flap

## LYMPHATIC IMAGING

Ongoing debate regarding the best non-invasive method for visualising lymph vessels could be the reason why the lymphatic system is often neglected and thus not adequately managed. Considerable advances in lymphatic imaging have been made over the last decade. A useful imaging technique for differential diagnosis and to exclude malignancies is the magnetic resonance imaging (MRI). The computed tomography (CT) and ultrasound mainly give structural indications, being the signs of a failing lymphatic system<sup>5</sup>. However, it would be highly useful to be able to image functional status of the lymphatic system itself. For determining functional signs there are various techniques including intradermal injection of Patent Blue, radionuclide lymphoscintigraphy with <sup>99m</sup>Tc labelled human serum albumin or <sup>99m</sup>Tc sulphur colloid. Both are classified as invasive measurements<sup>5</sup> so this might contribute to a reticence in their use as not only is the patient exposed to ionising radiation but also it has been found that nephrogenic systemic fibrosis has been associated with the contrast fluid<sup>38</sup>. In view of these negatives, the use



of Indocyanine Green (ICG) has been gaining popularity and is being increasingly introduced into practice.

ICG is a water-soluble tricarbo-cyanine dye which has clinically been used for the imaging of cardiac output, hepatic function and retinal vascularisation<sup>45</sup>. This fluorescing contrast agent associates with proteins and is made visible with excitation light and recorded with a near infrared camera system. ICG is considered a safe and non-invasive technique that provides accurate functional lymphatic imaging. Skin is relatively transparent to ICG with near infrared imaging and a clear, real-life image can be obtained without scattering of the (visible) light. The research team of Furukawa *et al.*<sup>46</sup> used ICG fluorescence lymphography to assist the excision of in-transit metastatic melanoma<sup>46</sup>. The fluorescence of ICG is within the near infrared spectrum range (approximately 800 nm) and this makes the dermal lymphatics visible. This research showed repeatability of the test, with easy interpretation and it seems to be more cost-effective than lymphoscintigraphy<sup>46</sup>. The usefulness of ICG has been proven in skin and breast cancer sentinel lymph node biopsy as a real-time fluorescence tracer<sup>47,48</sup>. Most recently it has also been used in sentinel lymph node biopsy in gastric cancer and gynaecological cancer surgery<sup>49,50</sup>. Holm *et al.*<sup>51</sup> observed that certain haemodynamic and intrinsic metabolic pathways are invaluable for wound healing and postoperative outcomes<sup>51</sup>. However, neither the lymphatic system nor its contribution in wound healing and tissue homeostasis is

mentioned in this review. This review argues the need for clinical studies with fluorescence dye intraoperatively as the best possible outcome for tissue survival and skin viability<sup>51</sup>.

## ICG IN LYMPHATIC FUNCTION ASSESSMENT

We consider the use of ICG and near infrared camera system as an ideal method to assess the incidence of local and generalised lymphoedema in patients who have had severe lower leg trauma with associated soft tissue injury. We have identified a cohort of 70 patients who have suffered severe open tibial fractures (Gustillo-Anderson IIIB) as a result of trauma between 2006 and 2012. Patients underwent soft tissue reconstruction with importation of either local or free tissue for wound coverage and have a variable degree of ongoing deficit and lymphoedema. Assessment of lymphatic function will involve intradermal ICG injection in correlation with established measures of lymphoedema and functional assessment. In addition, a prospective arm will be commenced that will recruit patients in the acute phase of recovery from such injuries to assess the timeline of lymphatic recovery.

A longitudinal follow-up of these patients will give us a picture of lymphatic regeneration in response to injury and the contribution of the imported flap tissue to lymphatic function and limb recovery. Such information will contribute to the knowledge of the recovery process of the lymphatic system in response to injury and hopefully

## Innovation is Negative Pressure Wound Therapy that's simple

Smith & Nephew develop products that help wounds heal, allowing people to return to normal life faster.

PICO® is simplified Negative Pressure Wound Therapy (NPWT) for acute and chronic wounds. The unique 4-layer dressing allows effective exudate management without the need for a bulky canister. Combined with a disposable pocket sized pump this makes NPWT accessible to more types of wounds, patients and clinicians.

This innovation to heal is just one product from the Smith & Nephew advanced wound care portfolio, where you'll find a solution for many different types of wounds.

PICO®



**smith&nephew**  
For patients. For budgets. For today.®

PICO® • ALLEVYN® • ACTICOAT® • DURAFIBER® • IV3000® • OPSITE® POST-OP VISIBLE

®Trademark of Smith & Nephew SN10162

Australia: T 13 13 60 [www.smith-nephew.com.au/healthcare](http://www.smith-nephew.com.au/healthcare)

New Zealand: T 0800 807 663 [www.smith-nephew.com/nz](http://www.smith-nephew.com/nz)

provide insights into the early management of lymphoedema and improvement of outcomes following lower limb trauma.

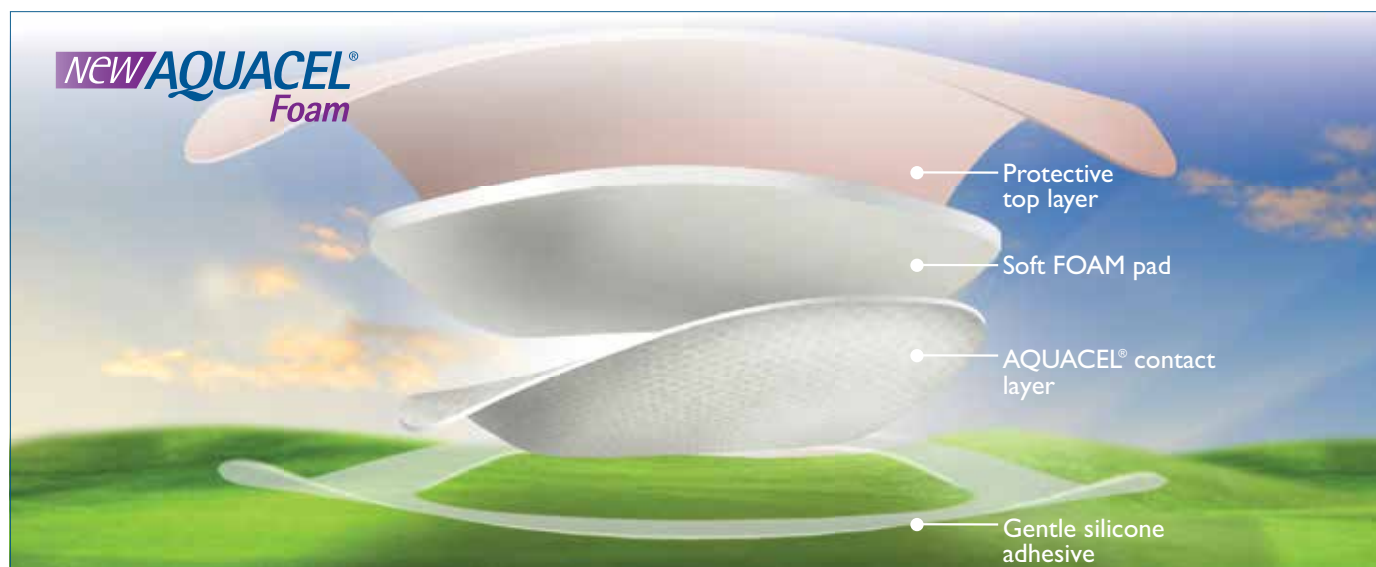
## ACKNOWLEDGEMENTS

This study is being performed in conjunction with the Department of Plastic and Reconstructive Surgery, Royal Adelaide Hospital. In particular the authors wish to acknowledge contributions by Mr Yugesh Caplash and Dr Andrew Campbell-Lloyd. Institutional ethics board approval had been acquired and there are no conflicts of interest to declare. Assessments are undertaken as per protocol of the Lymphoedema Research Unit at Flinders Medical Centre in Adelaide. We intend to report full trial outcomes in a future issue of the journal.

## REFERENCES

1. Zuther JE. Lymphedema management: the comprehensive guide for practitioners. New York: Thieme, 2005.
2. Földi M, Földi E, Strössenreuther RHK & Kubik S. Földi's textbook of lymphology: for physicians and lymphedema therapists. München: Elsevier Urban & Fischer, 2012.
3. Norrmén C, Tammela T, Petrova TV & Alitalo K. Biological basis of therapeutic lymphangiogenesis. *Circulation* 2011 Mar 29; 123(12):1335–51. PubMed PMID: 21444892. English.
4. Saladin KS. Anatomy & physiology: the unity of form and function. New York, NY: McGraw-Hill, 2007.
5. Lee B-B, Bergan JJ & Rockson SG. Lymphedema a concise compendium of theory and practice. London: Springer, 2011.
6. Levick JR & Michel CC. Microvascular fluid exchange and the revised Starling principle. *Cardiovasc Res*. 2010 Jul 15; 87(2):198–210. PubMed PMID: 20200043. English.
7. Partsch H & Moffatt C. An overview of the science behind compression bandaging for lymphoedema and chronic oedema. Best Practise for the management of lymphoedema Compression Therapy: A position document on compression bandaging [Internet]. 2012 30/03/2013; 2:[12–23 pp.]. Available from: <http://www.lympho.org/resources.php>.
8. Sajid S, Kazmi H, Strandén E *et al*. Edema in the Lower Limb of Patients Operated on for Proximal Femoral Fractures. *J Trauma* 2007; 62:701–7.
9. Parrett BM, Matros E, Pribaz JJ & Orgill DP. Lower extremity trauma: trends in the management of soft-tissue reconstruction of open tibia-fibula fractures. *Plast Reconstr Surg* 2006 Apr; 117(4):1315–22; discussion 23–4. PubMed PMID: 16582806. English.
10. Meiklejohn JA, Heesch KC, Janda M & Hayes SC. How people construct their experience of living with secondary lymphoedema in the context of their everyday lives in Australia. *Support Care Cancer* 2013; 21(2):459–66. English.
11. Macdonald JM, Sims N & Mayrovitz HN. Lymphedema, lipedema, and the open wound: the role of compression therapy. *Surg Clin North Am* 2003 Jun; 83(3):639–58. PubMed PMID: 12822730. English.
12. National Breast and Ovarian Cancer Centre (NBaOC). Review of research evidence on secondary lymphoedema: incidence, prevention, risk factors and treatment. Surrey Hills, NSW: NBaOC, 2008.
13. Földi M, Földi E, Strössenreuther RHK & Kubik S. Földi's textbook of lymphology: for physicians and lymphedema therapists. München, Germany: Elsevier, Urban & Fischer Verlag, 2012.
14. Curtis K, Caldwell E, Delprado A & Munroe B. Traumatic Injury in Australia and New Zealand. *Australas Emerg Nurs J* 2011; 15(1):45–54.
15. Bradley C & Harrison JE. Descriptive epidemiology of traumatic fractures in Australia. Canberra: Australian Institute of Health and Welfare, 2004.
16. Kreisfeld R & Harrison JE. Australian Institute of Health and Welfare. Hospital separations due to injury and poisoning 2005–06. Canberra: Australian Institute of Health and Welfare, 2010.
17. Gotschall CS. The Functional Capacity Index, second revision: morbidity in the first year post injury. *Int J Inj Contr Saf Promot*. 2005 Dec; 12(4):254–6. PubMed PMID: 16471159.
18. O'Toole RV, Castillo RC, Pollak AN, MacKenzie EJ, Bosse MJ & Group LS. Determinants of patient satisfaction after severe lower-extremity injuries. *J Bone Joint Surg Am* 2008 Jun; 90(6):1206–11. PubMed PMID: 18519312. Pubmed Central PMCID: 2657303. English.
19. Faschingbauer M, Meiners J, Schulz AP, Rudolf K-D & Kienast B. Operative Treatment and Soft Tissue Management of Open Distal Tibial Fractures — Pitfalls and Results. *Eur J Trauma Emerg Surg. Focus on Distal Tibial Fractures*. 2009; 35:527–31.
20. Hamblen DL, Simpson AHRW & Adams JC. Adams's outline of fractures, including joint injuries. Edinburgh, New York: Churchill Livingstone Elsevier, 2007.
21. Parrett BM & Pribaz JJ. Lower extremity reconstruction. *Revista Medica Area Academica De Clinica Las Condes* 2010; 21(1):66–75.
22. Balogh Z. Traumatology in Australia: provision of clinical care and trauma system development. *ANZ J Surg* 2010 Mar; 80(3):119–21. PubMed PMID: 20575906. English.
23. Zalavras CG, Marcus RE, Levin S & Patzakis MJ. Selected Instructional Course Lectures. Management of Open Fractures and Subsequent Complications. *J Bone Joint Surg* 2007; 89A(4):883–95.
24. Park J & Yang KH. Treatment of an open distal tibia fracture with segmental bone loss in combination with a closed proximal tibia fracture: a case report. *Arch Orthop Trauma Surg* 2012 Aug; 132(8):1121–4. PubMed PMID: 22526200.
25. Sussman C & Bates-Jensen BM. Wound care: a collaborative practice manual for health professionals. Philadelphia: Wolters Kluwer Health/Lippincott Williams & Wilkins, 2012.
26. Breier G. Lymphangiogenesis in Regenerating Tissue: Is VEGF-C Sufficient? *Circ Res* 2005; 96:1132–4.
27. Velnar T, Bailey T & Smrkolj V. The wound healing process: an overview of the cellular and molecular mechanisms. *J Int Med Res* 2009 Sep–Oct; 37(5):1528–42. PubMed PMID: 19930861. English.
28. Flour M. Dermatological issues in lymphoedema and chronic oedema. International Lymphoedema Framework Position Document, 2012.
29. Burns JL, Mancoll JS & Phillips LG. Impairments to wound healing. *Clin Plast Surg* 2003; 30(1):47–56. English.
30. Nogami M, Hoshi T, Arai T, Toukairin Y, Takama M & Takahashi I. Morphology of lymphatic regeneration in rat incision wound healing in comparison with vascular regeneration. *Leg Med (Tokyo)* 2009 Sep; 11(5):213–8. PubMed PMID: 19631569. English.
31. Macdonald JM & Ryan TJ. Lymphoedema and the chronic wound: the role of compression and other interventions. In: Macdonald G (Ed). Wound and lymphoedema management. Geneva: World Health Organisation, 2010, pp. 63–85.
32. Bui DT, Cordeiro PG, Hu QY, Disa JJ, Pusic A & Mehrara BJ. Free flap re-exploration: indications, treatment, and outcomes in 1193 free flaps. *Plast Reconstr Surg* 2007 Jun; 119(7):2092–100. PubMed PMID: 17519706. English.
33. Kraemer R, Lorenzen J, Knobloch K *et al*. Free flap microcirculatory monitoring correlates to free flap temperature assessment. *J Plast Reconstr Aesthet Surg* 2011 Oct; 64(10):1353–8. PubMed PMID: 21664205.
34. Salgado CJ, Moran SL & Mardini S. Flap monitoring and patient management. *Plast Reconstr Surg* 2009 Dec; 124(6 Suppl):e295–302. PubMed PMID: 19952698. English.
35. Slavin SA, Upton J, Kaplan WD & Van den Abbeele AD. An investigation of lymphatic function following free-tissue transfer. *Plast Reconstr Surg* 1997 Mar; 99(3):730–41; discussion 42–3. PubMed PMID: 9047193.
36. Khazanchi RK, Rakshit K, Bal CS, Guleria S, Sinha S & Srivastava A. Evaluation of lymphatic drainage in free flaps by lymphoscintigraphy: a preliminary study. *Br J Plast Surg* 1996 Mar; 49(2):123–8. PubMed PMID: 8733354. English.

37. Szczesny G, Olszewski WL, Gewartowska M, Zaleska M & Gorecki A. The healing of tibial fracture and response of the local lymphatic system. *J Trauma* 2007 Oct; 63(4):849–54. PubMed PMID: 18090016.
38. Lohrmann C, Pache G, Felmerer G, Foeldi E, Schaefer O & Langer M. Posttraumatic edema of the lower extremities: evaluation of the lymphatic vessels with magnetic resonance lymphangiography. *J Vasc Surg* 2009 Feb; 49(2):417–23. PubMed PMID: 19216961.
39. Cohen MD. Complete decongestive physical therapy in a patient with secondary lymphoedema due to orthopedic trauma and surgery of the lower extremity. *Phys Ther* 2011; 91(11):1618–26.
40. Szczesny G & Olszewski WL. The pathomechanism of posttraumatic edema of lower limbs: I. The effect of extravasated blood, bone marrow cells, and bacterial colonization on tissues, lymphatics, and lymph nodes. *J Trauma* 2002 Feb; 52(2):315–22. PubMed PMID: 11834995.
41. Szczesny G & Olszewski WL. The pathomechanism of posttraumatic edema of the lower limbs: II — Changes in the lymphatic system. *J Trauma* 2003 Aug; 55(2):350–4. PubMed PMID: 12913648.
42. Moffatt CJ, Franks PJ, Doherty DC *et al.* Lymphoedema: an underestimated health problem. *QJM* 2003 Oct; 96(10):731–8. PubMed PMID: 14500859. English.
43. Hoogendoorn JM & van der Werken C. Grade III open tibial fractures: functional outcome and quality of life in amputees versus patients with successful reconstruction. *Injury* 2001 May; 32(4):329–34. PubMed PMID: 11325370. English.
44. MacKenzie EJ, Bosse MJ, Pollak AN *et al.* Long-term persistence of disability following severe lower-limb trauma. Results of a seven-year follow-up. *J Bone Joint Surg Am* 2005 Aug; 87(8):1801–9. PubMed PMID: 16085622.
45. Suami H, Chang DW, Yamada K & Kimata Y. Use of indocyanine green fluorescent lymphography for evaluating dynamic lymphatic status. *Plast Reconstr Surg* 2011; 127(3). English.
46. Furukawa H, Hayashi T, Oyama A, Takasawa A & Yamamoto Y. Tailored excision of in-transit metastatic melanoma based on indocyanine green fluorescence lymphography. *Eur J Plast Surg* 2012; 35(4):329–32. English.
47. Fujiwara M, Mizukami T, Suzuki A & Fukamizu H. Sentinel lymph node detection in skin cancer patients using real-time fluorescence navigation with indocyanine green: preliminary experience. *J Plast Reconstr Aesthet Surg* 2009; 62(10):e373–e8. English.
48. Suami H, Chang D, Skoracki R, Yamada K & Kimata Y. Using indocyanine green fluorescent lymphography to demonstrate lymphatic architecture. *J Lymphoedema* 2012; 7(2):25–9.
49. Akita S, Mitsukawa N, Rikihisa N *et al.* Early diagnosis and risk factors for lymphedema following lymph node dissection for gynecologic cancer. *Plast Reconstr Surg* 2013 Feb; 131(2):283–90. PubMed PMID: 23357989. English.
50. Miyashiro I, Hiratsuka M, Kishi K *et al.* Intraoperative diagnosis using sentinel node biopsy with indocyanine green dye in gastric cancer surgery: an institutional trial by experienced surgeons. *Ann Surg Oncol* 2013; 20(2):542–6. English.
51. Holm C, Mayr M, Höfter E, Becker A, Pfeiffer UJ & Mühlbauer W. Intraoperative evaluation of skin-flap viability using laser-induced fluorescence of indocyanine green. *Br J Plast Surg* 2002; 55(8):635–44. English.



## Everything you love about foam dressings *and more*

**Now** only one dressing offers the comfort and simplicity of FOAM plus the healing benefits of an AQUACEL® contact layer

AQUACEL®, the AQUACEL logo, ConvaTec, the ConvaTec logo, Hydrofiber and the Hydrofiber logo are trademarks of ConvaTec Inc., and are registered trademarks in the U.S. © 2013 ConvaTec Inc.

ConvaTec (Australia) Pty Limited. ABN 70 131 232 570. Unipark Monash, Building 2, Ground Floor, 195 Wellington Road, Clayton VIC 3168 Australia. PO Box 63, Mulgrave, VIC 3170. Phone: (03) 9239 2700 Facsimile: (03) 9239 2742. Customer Support Freecall: 1800 339 412. ConvaTec (New Zealand) Limited. AK2135265 PO Box 62663, Greenlane 1546 New Zealand. Phone: 0800 441 763. www.convatec.com.au June 2013 ADW045

