

Use of hydrocolloid protective sheets to protect skin against direct contact from body secretions

ABSTRACT

Hydrocolloid protective sheets provide a moist favourable environment for wound healing and act as a barrier against exogenous bacteria. They do not adhere to the wound, only to the surrounding skin, and can provide more a more rapid wound healing environment, keeping newly healed skin intact and preventing breakdown of tissue. Hydrocolloid protective sheets do not traumatise the skin upon removal, reducing pain, and require fewer dressing changes as they may be left in place for several days at a time. They come in different sizes which can be custom-cut to fit the wound. Their use can also reduce the cost of care, length of stay in hospital and amount of care rendered by WOC nurses. The three case studies in this article describe how stomal therapy nurses approached the nursing management of denuded skin using hydrocolloid protective sheets on peristomal skin, the buttocks and perineal regions.

Keywords hydrocolloid, protective sheet, MASD, IAD, denuded

For referencing Tan NM et al. Use of hydrocolloid protective sheets to protect skin against direct contact from body secretions. WCET® Journal 2021;41(4):18-21

DOI <https://doi.org/10.33235/wcet.41.4.18-21>

Submitted 26 April 2021, Accepted 18 July 2021

INTRODUCTION

MASD (moisture-associated skin damage) is caused by prolonged exposure to different sources of moisture. These include perspiration, urine output, faecal output, wound exudate, mucus, saliva, other secretions, and their contents. When excessive moisture, including its chemical content and mechanical factors such as friction and presence of pathogenic organisms, leads to inflammation of the skin, with or without erosion or secondary cutaneous infection, MASD occurs¹.

Nur Madalinah Tan* ET, RN, WOCNC Singapore
Colorectal Nurse, Specialty Nursing, Changi General Hospital, 2, Simei Street 3, Singapore 529889
Email Madalinah_tan@cgh.com.sg

Josephine Ong RN
Colorectal Nurse, Specialty Nursing, Changi General Hospital, Singapore

Feng Ying RN
Hepatopancreatobiliary Nurse, Specialty Nursing, Changi General Hospital, Singapore

Ong Ling ET, RN
Wound Healing Society Singapore, Wound Care Nurse, Specialty Nursing, Changi General Hospital, Singapore

Catherine Loo ET, RN
Wound Care Nurse, Specialty Nursing, Changi General Hospital, Singapore

*Corresponding author

Incontinence-associated dermatitis (IAD) is one common form of MASD. IAD is a type of irritant dermatitis found in patients with faecal and/or urinary incontinence. It is also known as perineal dermatitis or nappy/diaper rash. Sometimes it is associated with bullae, erosion or a secondary cutaneous infection^{2,3}.

Stomal prolapse, where the intestine telescopes through the stoma, is a common postoperative complication and is often associated with loop colostomies. Common reasons for stomal prolapse are surgical technique, obesity, increased abdominal pressure, and creation of the stoma outside of the abdominus rectus muscle. Prolapsed stomas can contribute to leakage around the stoma, leading to significant skin irritation or IAD^{4,5}.

Persistent exposure to large amounts of moisture will cause the skin to soften, swell, and become very wrinkled^{1,3}. This will damage the skin and reduce skin barrier function, leading to skin erosion, causing the patient to suffer pain, trauma, emotional stress, and financial strain^{1,4,6}. Patients will generally report experiencing pain, burning or itching because of skin damage; this may also involve frequent trips to visit nurses or long-term stays in hospital. Activities of daily living may also be affected, and there may be financial constraints due to not being able to work and the high cost of expenses and travelling⁶.

The general principles to prevent and treat MASD and IAD are to use a structured skincare regimen using products to remove excess moisture from the skin, and therefore protecting the

skin from infection and managing the source of moisture³. As such, patients at high risk for developing MASD and IAD require complications to be minimised when exhibiting symptoms by monitoring the wound area routinely for changes in skin condition, managing exudate with appropriate dressings for proper absorbency, and applying a skin barrier or skin protectant to the peristomal / periwound skin when appropriate^{1,2,7,8}. The management of stomal prolapses is based on individual patient assessment and many include local reduction of the prolapse, surgical revision, re-evaluation of the ostomy appliance to fit the size and shape of the stoma, and the use of a hernia support belt encompassing a prolapse strap⁴.

Hydrocolloid protective sheets contain CMC (carboxymethyl-cellulose), pectin or gelatin combined with adhesive and tackifiers applied to polyurethane foam or film carrier to create an absorbent, self-adhesive sheet⁹. This provides an occlusive bacterial and viral barrier, reducing the risk of cross infection, lowering the wound pH, reducing bacteria proliferation, maintaining moisture at the wound bed, enhancing epithelisation and lower levels of pain, and preventing desiccation of the wound bed, therefore providing a moist wound healing environment⁹.

Hydrocolloid protective sheets can be used on a wide range of low to moderate exuding wounds and on a variety of wound shapes and sizes. They are simple to apply and can be used under the stoma wafer or directly on the denuded skin in the perineal, groin and sacral regions. They absorb moisture, minimising the risk of skin to be denuded, therefore further reducing contact with effluent and allowing the skin to heal if there is a previous skin issue. They are also good for skins that have irritation and allergies⁹. These sheets come in two sizes in my organisation and are not to be used for extended wear. They can also be used over other things like barrier rings and ostomy powder.

The sheets can be used in addition to a crusting or layering skin protection method which also uses skin barrier powder and a skin barrier spray. The skin barrier powder helps to absorb moisture and dries the wound as well as provides a seal. The skin barrier spray is then used to seal the powder to the skin before the protective sheets are placed over the top. This action must be repeated three times to be effective. This method was taught by the WOCN curriculum and passed down to peers⁴.

CASE STUDIES

Case study 1

Patient overview

A 61-year-old Chinese male patient underwent relook laparotomy, washout, decompression of small bowel and double barrel ileocolostomy creation on 11 February 2019. The patient and wife were taught how to manage the changing of the wafer during his stay in hospital and his outpatient visits to the colorectal nurse. He also had two home visits to ensure his competency in ostomy care.

From July to October 2019 the patient visited the outpatient clinic for a prolapsed stoma (distal loop prolapsed approximately 10cm, proximal loop prolapsed approximately 3cm) which was reducible to skin level. The patient was advised to use a hernia support belt to minimise the frequency of incidents of the stoma prolapsing. The peristomal skin was still intact.

The long-term operative plan was for stoma reversal in October but during his visit to the surgeon it was noted the ostomy appliance had obviously been leaking for sometime. The patient was re-referred to the colorectal nurse for review of the leaking appliance and treatment of denuded skin before his surgery.

Problem

On review, the patient was using a poorly fitted two-piece system and severe leakage was observed, yet, while the patient reported frequent leakage, he said he was able to manage. However, on assessment, it was observed to be more severe than described. He claimed that he was unable to change his appliance promptly as he did not bring a spare appliance during his clinic visit (Figure 1).

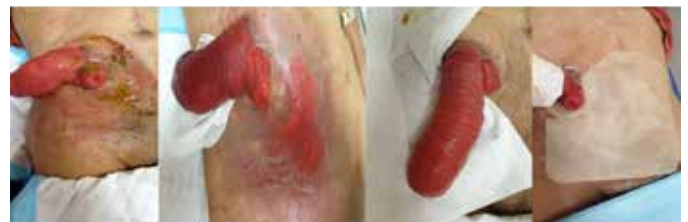

Figure 1. Case study 1: Day 1, 1 October 2019 (photos@Madalinah 2020)

Nursing intervention

During his first visit, the skin was cleansed with a non-rinse skin cleanser to restore the pH balance of the skin. The stoma was reduced to relieve tension and facilitate pouching and management. Ostomy powder was applied to absorb moisture and a skin barrier spray was used for enhanced skin protection. The patient expressed that he was comfortable with using a two-piece system despite being advised that the plastic flange may injure his stoma. A protective skin barrier was applied over the denuded skin ensuring a margin 1/3 above and 2/3 below the abdomen. The patient was advised to continue using the hernia support belt. On Day 4 there were signs of skin epithelisation (Figure 2). By Day 8, the skin was fully epithelised (Figure 3).

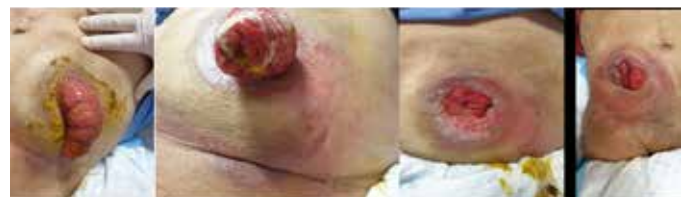

Figure 2. Case study 1: Day 4, 4 October 2019 (photos@Madalinah 2020)

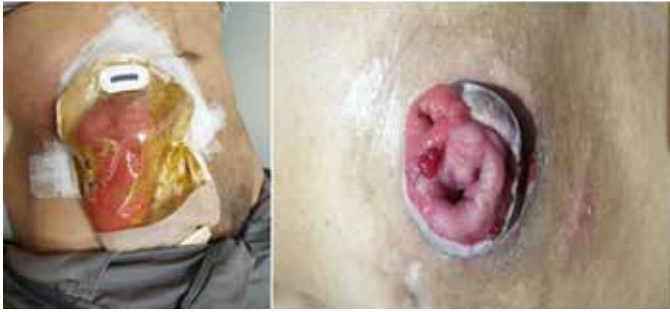

Figure 3. Case study 1: Day 8, 8 October 2019 (photos@Madalinah 2020)

Case study 2

Patient overview

A 70-year-old female was admitted for IAD with denuded skin over her right lower buttock, perianal to bilateral labial majora. She was non-communicative; her son was her main caregiver. The patient was bed-bound, on nasogastric tube feeding and had an in-dwelling catheter.

Problem

The patient was referred on 24 September 2019 (Day 1). On assessment it was noted there were healed scars from previous episodes of impaired skin integrity. At that time, the tissue was erythematous and weeping and her skin temperature was warm to touch (Figure 4). The patient was observed to be teary and agitated.

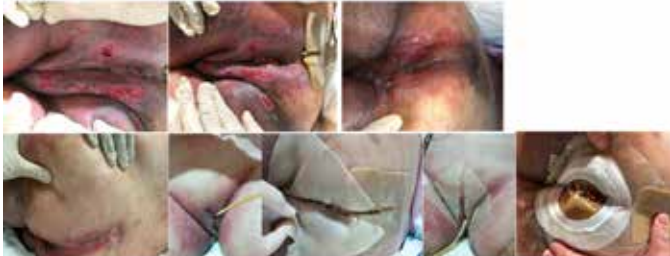

Figure 4. Case study 2: Day 1, 24 September 2019 (photos@Ong Ling/Catherine 2020)

Nursing intervention

Normal saline 0.9% was used to cleanse the wound; ostomy powder and a skin barrier spray were used to protect the skin by the crusting method and a hydrocolloid protective sheet was used to then protect the skin. It was recommended to nurses on the ward that they continued to wash the vagina area at every nappy change for good perianal hygiene and to ensure frequent turning to offload pressure. Skin cleansing was done to the buttock and perineal areas using a non-rinse skin cleanser, crusting with ostomy powder, and a skin barrier spray. A hydrocolloid protective sheet was applied to the bilateral groin, bilateral labial majora and perianal area. On 27 September (Day 3), skin epithelisation was observed, and the skin temperature was cool to the touch (Figure 5). Further improvement could be seen on Day 6 (Figure 6); the patient was discharged on 4 October once the skin had fully epithelised over.

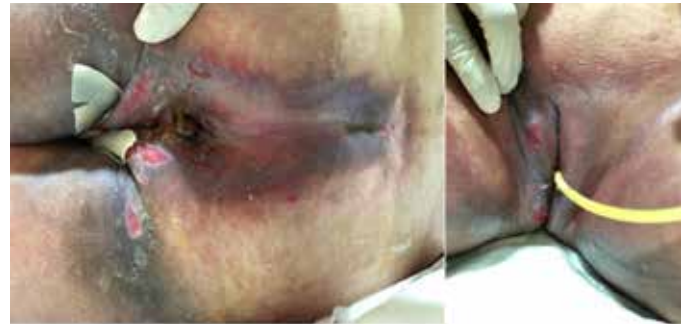


Figure 5. Case study 2: Day 3, 27 September 2019 (photos@Ong Ling/Catherine 2020)

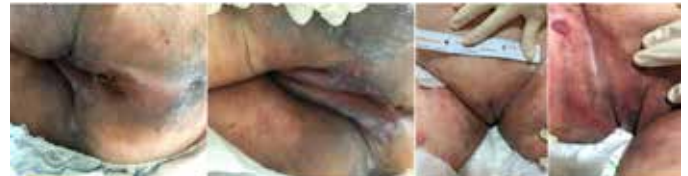

Figure 6. Case study 2: Day 6, 30 September 2019 (photos@Ong Ling/Catherine 2020)

Case study 3

Patient overview

The patient was an 86-year-old Chinese female patient with a past medical history of hypertension, hyperlipidaemia and cataracts; her maid was the main caregiver at home. She had had a laparoscopic appendicectomy and a robotic assisted laparoscopic ultra low anterior resection and defunctioning ileostomy created in May 2018. She was scheduled for a planned elective admission for laparoscopic Hartmann's reversal on 24 February 2019; however, the patient had watery, non-bloody stool 3–4 times per day 2 weeks prior to admission.

Problem

On assessment at the outpatient clinic, gross erythema over the left abdomen was noted; the skin was also weepy and denuded, the ostomy appliance was reinforced with Tegaderm™, and the patient was also using nappies. The skin looked like a mixture of contact dermatitis and fungal infection (Figure 7).

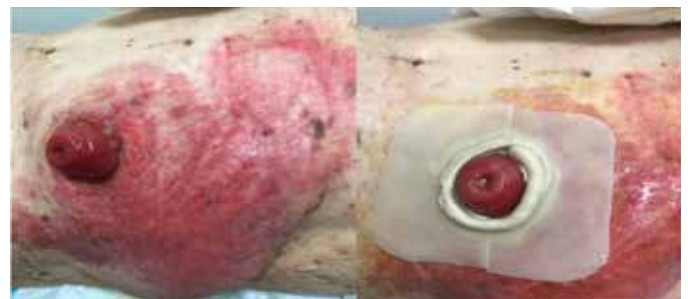

Figure 7. Case study 3: Day 1, 10 February 2019 (photos@Madalinah 2020)

Nursing intervention

It was recommended by the stomal therapy nurses to discontinue the use of nappies and Tegaderm™, and to cleanse

the skin with non-rinse skin cleanser, paint with povidone iodine, protect with ostomy powder and skin barrier spray by the crusting method. A sheet of protective hydrocolloid was cut to the size and shape of the stoma and placed around the stoma to protect the immediate peri-stomal skin (Figure 7).

On 15 February 2019 (Day 5) the patient returned to the outpatient clinic for review; the skin was observed to have dried up with scabs, was cool to touch, and was not weeping. A protective hydrocolloid sheet was reapplied after the skin care regimen described above (Figure 8). On 22 February 2019 (Day 12), the patient's skin had healed significantly with only light erythema present with no signs of previous scars within the healed tissue (Figure 9). During the remainder of her admission the protective hydrocolloid sheet was to protect the peristomal skin. The patient was discharged on 24 February 2019 and a protective sheet was still used to protect the skin until her elective admission.

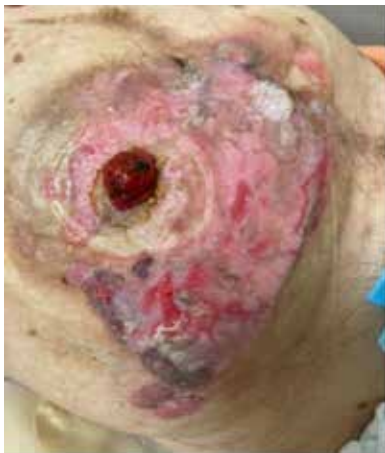

Figure 8. Case study 3: Day 5, 15 February 2019 (photos@Madalinah 2020)



Figure 9. Case study 3: Day 12, 22 February 2019 (photos@Madalinah 2020)

CONCLUSION

The maintenance of skin integrity provides a foundation for long-term success in the rehabilitation of patients with skin issues. The use of hydrocolloid skin barriers provides a moist environment which allows the body enzymes to improve healing as they do not stick to the skin. The authors have had positive experiences using these, as shown by the three case studies shared here, but they are not favourable for wounds with heavy exudate or sinus tracts, or when infection is present. There are two sizes available in our hospital and they are self-adhering, making them easy to use for various body areas. However, the edges may curl or roll; that is why the authors use micropore tape as reinforcement. Frequency of change can vary from 3–7 days depending on the amount of exudate and on manufacturers' guidelines. With ongoing use for selected

patients, the authors are sure a positive result will be achieved showing similar benefits.

CONFLICT OF INTEREST

The authors declare no conflicts of interest.

FUNDING

The authors received no funding for this study.

REFERENCES

1. Gray M, Black JM, Baharestani MM, Bliss DZ, Colwell JC, Goldberg M, Kennedy-Evans KL, Logan S, Ratliff CR. Moisture-associated skin damage: overview and pathophysiology. *J WOCN* 2011 May-Jun;38(3):233-41. doi:10.1097/WON.0b013e318215f798.
2. Yates A. Incontinence-associated dermatitis 1: risk factors for skin damage. *Nursing Times* 2020;116:3,46–50.
3. Ousey K, O'Connor L. Incontinence-associated dermatitis made easy. London: Wounds UK; 2017. Available from: www.wounds-uk.com
4. Pitman. Stoma complications. In: Carmel JE, Colwell JC, Goldberg MT, editors. *Wound Ostomy and Continence Nurses Society core curriculum ostomy management*. China: Wolters Kluwer; 2016. p. 191–200.
5. Colwell JC, Ratcliff CR, Goldberg M, et al. MASD part 3: peristomal moisture-associated dermatitis and periwound moisture-associated dermatitis: a consensus. *J WOCN* 2011;38(5):541–53.
6. Chabal LO, Prentice JL, Ayello EA. Practice implications from the WCET® International Ostomy Guideline 2020. *Adv Skin Wound Care* 2021;34:293–300. doi:10.1097/01.ASW.0000742888.02025.d6
7. Beeckman D, Van den Bussche K, Alves P, Beele H, Ciprandi G, Coyer F, et al. The Ghent Global IAD Categorisation Tool (GLOBIAD). *Skin Integrity Research Group (SKINT)*, Ghent University; 2017. Available from: <https://users.ugent.be/~dibeeckm/globiadnl/nlv1.0.pdf>
8. Zulkowski K. Understanding moisture-associated skin damage, medical adhesive-related skin injuries, and skin tears. *Adv Skin Wound Care* 2017;30(8):372–38.
9. Ousey K, Cook L, Young T, Fowler A. Hydrocolloids in practice made easy. *Wounds UK* 2012;8(1):1–6.